

CLINICAL AND RADIOGRAPHIC EVALUATION OF FIBER AND REVERSE METAL POSTS CEMENTED WITH THREE DIFFERENT MATERIALS IN PRIMARY INCISORS. A RANDOMIZED CLINICAL TRIAL

Ahmed Etman* 

ABSTRACT

Background: Preservation of primary incisors with extensive carious lesions represents a challenge in dental clinics. Extraction and replacement of these teeth by removable or fixed appliances may represent a big dilemma regarding gingival health and the patients Cooperation. **Objectives:** The aim of this study was to compare three various techniques used for restoring primary anterior teeth with extensive carious lesions regarding success and failure and mode of failure.

Materials and Methods: Thirty children of both genders with ages 3 to 5 years participated in the study. The children were conveniently selected and randomly allocated into three different groups. Each group included 10 children (every child had one central and one lateral primary incisor tooth): Group I: in which fiber post was cemented by dual-cured build-up composite core material. Group II: in which fiber post was cemented by dual cure resin cement. Group III: in which reverse metal post was cemented by zinc phosphate cement.

Results: Regarding success and failure by the end of follow up period, 20% of cases failed in group I (4 cases) while only 10 % of cases in group II (2 cases) and 15 % in group III (three cases) failed. Regarding the mode of failure among the studied groups, one case in group I and group II failed due to root fracture during the follow up period while 3 cases of failure in group III happened due to core fracture. Post ponding induced three cases of failure in group I and one case in group II.

Conclusion: fiber posts cemented with dual cure resin proved superior properties in comparison to either reversed metal post cemented by zinc phosphate cement or fiber posts cemented with build-up composite core.

KEYWORDS: Fiber post, dual cure resin, composite, reverse metal post, primary teeth

* Assistant Professor at Delta University for Science and Technology

INTRODUCTION

Early childhood caries is a great challenge in pediatric dentistry. It is a chronic, irreversible, multifactorial disease whose etiology is attributed to night-time feeding with cariogenic diet and poor oral hygiene habits⁽¹⁾. Maxillary central incisors and maxillary lateral incisors are the most affected teeth. Rapid spread of ECC induces esthetics problems beside many medical problems which affect the general health and dentition⁽²⁾. Child Cooperation and stage of decay must be considered the main factors affecting the proper restorations of primary anterior teeth⁽³⁾.

Retentive sources are mandatory before crown building in cases where teeth are severely destroyed. Conventional restorative treatment options like direct techniques using prefabricated crowns, as well as resin composite restorations may be ineffective due to absence of sufficient tooth structure and procedures of endodontic treatment and obturation⁽⁴⁾. Anterior stainless-steel crowns with or without labial facing for full crown coverage of incisors was used to accept retention sub gingivally, but this option was found to cause either aesthetic or gingival problems or both⁽⁵⁾. The key for successful treatment of these cases is, how to extract support from the remaining tooth structure (Root canal endodontically treated and obturated)?

Posts made from different materials were investigated for intracanal retention, resistance, and stability of the coronal structure. The Post size and extension in the root canal is essential in producing the retention and fracture resistance of the post. However, in primary teeth, posts are restricted to the coronal third of the root and may extend more apically in the middle third of the root if required to prevent arrest or ectopic eruption of permanent teeth⁽⁶⁾.

Recent advances try to increase the adhesive strength of the post, thereby reducing the extension of the post, hence preventing post and core fracture.

Some of these techniques are sensitive and require more skills from the operator as fiber posts cemented by either Dual cure adhesive resin⁽⁷⁾ or dual cure build-up composite core⁽⁸⁾ and others may be easier as reverse metal post cemented by zinc phosphate cement⁽⁹⁾. This study aimed at comparing the success and failure rates of three post and core application techniques in badly decayed primary anterior teeth; 1. fiber post cemented by dual cure build up composite resin, 2. fiber post cemented by dual cure adhesive resin, 3. reverse metal post cemented by zinc phosphate cement. The present study hypothesized no difference in success rates of the tested posts and cement materials.

MATERIALS AND METHODS

Study design and location

This randomized clinical trial was conducted between May 2022 and September 2023 at the Outpatient Pediatric Dental Clinics in Faculty of Dentistry, Delta University (DU).

Sample size calculation

Sample size calculation was performed using G*Power version 3.1.9.6 for Mac, depending on the result of a previous study⁽¹⁰⁾. A total sample of 27 children was calculated to detect small effects (effect size=0.6) with 80% power using Chi-square test for comparison between proportions at an alpha=0.05. Then the total number was increased to be 30 children to compensate for dropout during the study period.

Inclusion criteria:

Healthy cooperative children of both genders with age range from 3 to 5 years who fulfilled the following criteria participated in the study: having no malocclusion, no deleterious oral habits. Primary maxillary central and lateral incisors should be present with signs of sever coronal destruction (the destruction involved three fourths of the crown

structure). The central and lateral incisors should show enough root length (about two thirds). The teeth's root should not display signs of internal or external resorption. The selected teeth should not present mobility or subgingival crown destruction.

Randomization and participants' allocation into study's groups

Patients were conveniently selected according to the inclusion criteria, and then they were randomly allocated to the 3 test groups. The randomization process was carried out as follow; children were stratified into two groups according to their gender: males and females. Every child was assigned a specific number. Symmetrical papers were used for writing children's numbers and closed in the same way, then were placed in two bowls, one for males and the other for females. Every bowl contained 15 pieces of paper. The first withdrawn pieces; five pieces for males and five for females were assigned in group I, and so on for group II and III. So, each group contained 10 children, 5 males and females.

The selected children (30) were allocated into three groups. Group I: Fiber post (Fanta, China) was cemented by dual-cured build-up composite core (Meta Biomed, Korea). Group II: The fiber post (Fanta, China) was cemented using dual cure resin cement (S D I Riva, Australia). Group III: In which reverse metal post (IMD, China) was cemented by zinc phosphate cement (Harvard, Richer and Hoffman, Berlin, Germany).

Ethical approval and parent's consents

The proposal for this study was approved by the Ethics Committee of the Faculty of Dentistry at DU (FODMRC/DU2022-00115). Legal guardians of the study participants were informed about the aim and specific objectives of the research and the value of their children's participation. Furthermore, they were informed that participation was voluntary and that the children's identities would be kept anonymous and confidential. Written informed consents were

collected from parents/legal guardians prior to data collection stage.

Data collection

For all cases, Inclusion criteria was evaluated by clinical examination and Preoperative periapical radiograph. Removal of caries was done keeping intact hard dentine. Metapex was used as root canal obturating material for all the cases (Meta Biomed, Korea). 3-4mm space was made in the coronal portion of the obturated canal for the post cementation. The post was adjusted, and occlusion was checked.

In the first group, acid etching was used for conditioning the coronal portion of the root canal then rinsed and dried. Bonding agent (Ivoclar Vivadent, Switzerland) was applied to the remaining tooth structure and in the root canal and cured. The same bonding agent was applied to the fiber post and light cured. The Post was then immersed in build-up dual cure composite core (Ivoclar Vivadent, Switzerland) inserted in the root canal and then light cure was done. The coronal restoration was constructed incrementally by the buildup dual cure composite core. Occlusion was checked and final finishing was done ⁽¹¹⁾.

In the second group, the entire walls of the root canal and external tooth surfaces were conditioned by acid, for 20 seconds and then rinsed. Bonding agent (Ivoclar Vivadent, Switzerland) was applied to the entire area of the root canal and external tooth surfaces and light cured, and the entire surface of the post was coated by the bonding agent and light cured. Dual cure resin cement was manipulated then applied to the canal surface. At the same time, the resin cement was applied to the post and inserted into position and subjected to digital pressure until it reaches its height then light cured after removal of the excess unpolymerized resin cement, then the composite core was built up incrementally. Finally, the occlusion was adjusted using occluding paper

and then finishing and polishing was done ⁽¹²⁾.

In the third group, the adjusted reverse metal post was cemented into the canal using zinc phosphate cement after initial setting of the cement, etching with acid and rinsing was done to the threaded portion of post and remaining structure of teeth, the threaded part of the post was covered with one layer of flowable composite resin (Aelite flow, Kuraray Co., Osaka, Japan). The coronal restoration was constructed incrementally by composite (APX, Kuraray Co, Osaka) ⁽¹³⁾.

Follow-up periods and evaluation

Clinical evaluation was performed at baseline then after 1, 6 and 12 months for the success and failure of the post and core and for mode of failure. Restorations were also evaluated radiographically using periapical radiographs, at baseline and after 1, 6 and 12 months, using the following criteria: clinical or radiographic signs of failure, root fracture and post fracture.

Statistical analysis

The data were gathered, structured, and scrutinized by means of SPSS version 20.0 (IBM

Corp. Chicago, IL, USA). Standard descriptive statistics such as frequencies were computed to ascertain the features of the sample. The chi-square test was employed to compare two or more frequencies. A p value less than 0.05 was deemed statistically significant.

RESULTS

As shown in table 1 and figure 1, there was no failure among all the study groups after one month of follow-up. Six months later, three cases failed in group I with no cases of failure in group II and III. By the end of the follow up period (12 months), another case failed in group I, in addition to two cases in group II and three cases in group III.

Regarding the mode of failure among the studied groups, one case in group I and group II failed due to root fracture during all follow up periods, while 3 cases of failure in group III happened due to core fracture. No cases of failure due to post fracture or failure of pulp therapy among the three groups were seen during the follow up periods. Post depending induce three cases of failure in group I and one case in group II. (Table 2)

TABLE (1). Distribution of success and failure during follow up periods among study groups (20 teeth each)

Follow up periods	Group I		Group II		Group III		Test of significance
	Success n (%)	Failure n (%)	Success n (%)	Failure n (%)	Success n (%)	Failure n (%)	
One month	20(100%)	0	20(100%)	0	20(100%)	0	-
6 months	17(85%)	3(15%)	20(100%)	0	20(100%)	0	$\chi^2= 31.58$ P<0.0001*
12 months	16(80%)	4(20%)	18(90%)	2(10%)	17(85%)	3(15%)	$\chi^2= 4.94$ P= 0.08
Test of significance	$\chi^2= 2.45$ P= 0.29	$\chi^2= 18.57$ P<0.0001*	$\chi^2= 0.69$ P= 0.71	$\chi^2= 20.0$ P< 0.0001*	$\chi^2= 1.58$ P= 0.45	$\chi^2= 30.0$ P< 0.0001*	-

χ^2 : Chi-square test for comparison of success and failure rates between the three groups at different follow-up periods

*: Statistically significant difference at $p \leq 0.05$

TABLE (2). Distribution of mode of failure among studied groups during follow up periods

Mode of failure	Group 1		Group II		Group III		Total failure scores		Test of significance
	N	%	N	%	N	%	N	%	
Root fracture	1	5 %	1	5%	0	0	2	3.3%	$\chi^2= 5.0$ P= 0,08 $\chi^2=30.0$
Core fracture	0	0	0	0	3	15%	3	6.6%	P<0.0001
Post fracture	0	0	0	0	0	0	0	0	-
Post debonding	3	15%	1	5%	0	0	4	6.6%	$\chi^2=17.50$ P<0.0002
Failure of pulpectomy	0	0	0	0	0	0	0	0	-
Total number	4	20%	2	10%	3	15%	9	15%	$\chi^2=3.33$ P=0.19

χ^2 : Chi-square test for comparison of failure rates between the three groups

*: Statistically significant difference at $p \leq 0.05$

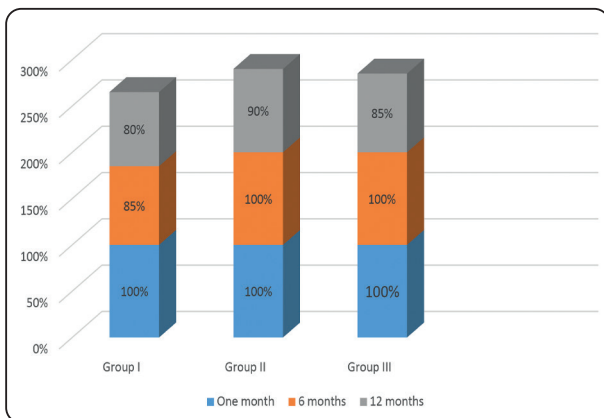


Fig. (1) Distribution of Success Rates Between Study Groups at Different Follow up periods

DISCUSSION

Accurate technique was required for restoration of decayed primary incisors with little amount of tooth structure, not only with regard to the retentive requirements but also regarding the variables in behavior management. The young age of the child needs short appointment and rapid technique to avoid adverse reactions (14). In the present study, comparison was made between three techniques, fiber post cemented by dual cure build-up composite core, fiber post cemented by dual cure resin cement and reversed metal post cemented by zinc phosphate cement. The present study represented an attempt to compare between three alternatives for such critical cases.

The friction between the post and the wall of the root canal was essential in all cases as a retentive method, hence the amount of tooth structure was little. In this study the metal post was reversed using the base within the canal instead of conventional threaded part, to avoid conventional anchor of threaded post to the tooth structure which always cause decementation and sometimes fracture of the tooth as a result of transmission of stress (15).

Fiber posts represent new advancement in treatment of such cases, the elastic modulus of it is similar to dentin so tend to absorb and scatter masticatory and traumatic stress like natural dentin, thereby protecting the root from fracture (16), however many factors may affect the success of fiber post cementation as moisture control required to apply the adhesive system, polymerization shrinkage, curing light ability to reach deeper areas in addition to the pores that may be present due to possible presence of thick layer of adhesives around the post (17).

In the present study, the adhesive system in the first and second groups was dual cured to achieve the advantages of both light and chemically activated resins beside adequate degree of curing and extended working time in light curing systems (18). In the first group, dual cure build-up composite core as used due to its better particle agglomeration,

no layering required with reliable polymerization and better handling⁽¹⁹⁾. In the second group, dual cure resin cement was selected due to low solubility in oral fluids with higher tensile and compressive strength when compared with zinc phosphate or glass ionomer⁽²⁰⁾

The possibility of gap formation or forming of air bubbles within the root canal was minimized by application of the cementing materials to both the root canal and the post followed by in and out movement of the post on the luting cement within the canal before fixation by the digit in its position.

A statistically significant difference was revealed between studied groups regarding the distribution of success and failure at six months of follow up, three cases failed in group I with no cases of failure in group II and III, while by the end of the follow up period (12 months), the ratio of success was 80 % with failure of 4 cases, 90 % with failure of 2 cases, and 85 % with failure of 3 cases in group I, II and III respectively (table 1). The mode of failure in group III (reversed metal post) were due to core fracture while the mode of failure in group I (4cases) and II (2 cases) were due to post decementation with catastrophic failure due to root fracture in two cases.

As seen, the use of reversed metal post gave a higher stability due to the quadrangle shape of the base with both friction and cementation, decreased to a higher extent the transmission of forces to the root structure, so the percentage of success was 100 % during the first six months. contra verse higher failure was presented after 12 months of follow up due to core fracture which may be attributed to the construction of the composite core on pointed end of the metal post which decreased area to tolerate forces or due to strain and stress concentrated on threaded post causing cracks to inner wall of the composite core⁽²¹⁾.

On the other hand, all the cases of failure in first and second groups were due to decementation. Many studies revealed that limited ability to diffuse light across the entire length compromising the degree of

polymerization and conversion. Interfacial gaps are always found in bonded posts^(22,23,24). While other studies revealed that Dual cure resins have adequate strength, ease of handling and they can be bonded to the tooth structure. Their compressive strength is comparable to amalgam cores^(25,26).

Many Studies showed that physical surface features as serrations^(27,28), the use of greater diameter of posts^(28,29) or the presence of a retentive head design at the coronal aspect of the post^(27,30) appear to be more significant with respect to improving retention of the post to the root and that of the core to the post, respectively. The latter features may improve the ability of the resin lute/core material to interlock to the resin fiber post⁽²⁷⁾.

CONCLUSION

The study hypothesis was rejected as; fiber post cemented with dual cure resin proved superior properties in comparison to either reversed metal post cemented with zinc phosphate cement or fiber posts cemented with composite build-up core.

REFERENCES

1. De Grauwe A, Aps JK, Martens LC. Early childhood caries (ECC): what's in a name? *Eur J Paediatr Dent* 2004; 5(2):62–70.
2. Hakan Çolak, Çoruh T. Dülgergil, Mehmet Dalli, Mehmet Mustafa Hamidi. Early childhood caries update: A review of causes, diagnoses, and treatments. *J Nat Sci Biol Med*. 2013, 4(1), 29–38.
3. Reisine S, Douglass JM. Psychosocial and behavioral issues in early childhood caries. *Community Dent Oral Epidemiol*. 1998; 26:32–44.
4. Srinivas NC, Jayanthi M. Post endodontic restoration of severely decayed primary dentition: a challenge to pediatric dental surgeon. *World J Dentis*. 2011; 2(1):67–69.
5. Mariana Dimova-Gabrovska, Desislava Dimitrova, Bozhidar Yordanov, Mariana Yankova, Todor Peev. Advantages and disadvantages of pediatric crown prosthetic treatment. *J of IMAB*. 2019; 25(3):2695–2700.
6. Ravi Ramakrishna; Rajesh Ragulakollu; Nama Ravikiran; Alankrutha Gangasani; Nallabolu Rashmika Reddy; Singh, Rohit. Root as a Novel Post and Core Material for

- Primary Teeth, A Case Report. *Journal of Pharmacy and Bioallied Sciences* 2020, 12 (1): S652-S655.
7. Chang Liu, Hong Liu, Yue-Tong Qian, Song Zhu & Su-Qian Zhao. The influence of four dual-cure resin cements and surface treatment selection to bond strength of fiber post. *International Journal of Oral Science* 2014, 6, 56–60.
 8. L. Spinhayer, A.T.B. Bui, J.G. Leprince & C.M.F. Hardya. Core build-up resin composites: an in-vitro comparative study. *Biomater Investig Dent* 2020; 7(1): 159–166.
 9. Alireza Eshghi, Raha Kowsari Esfahan & Maryam Khoroushi. A simple method for reconstruction of severely damaged primary anterior teeth. *Dent Res J*, 2011; 8(4): 221–225.
 10. Seba Ibrahim, Abdul Wahab Nourallah. Clinical and radiographic comparative study to evaluate the efficacy of restoring destroyed primary incisors using two different techniques—A pilot study. *Clinical and Experimental Dental research*, 2020; 6(5): 537-543.
 11. Renata Andreza Talaveira da Silva, Margareth Coutinho, Pedro Igor Cardozo, Larissa Alves da Silva & José Roberto Zorzatto. Conventional dual-cure versus self-adhesive resin cements in dentin bond integrity. *J Appl Oral Sci*. 2011 19(4): 355–362.
 12. Juthatip Aksornmuang, Masatoshi Nakajima & Junji Tagami. Effect of viscosity of dual-cure luting resin composite core materials on bond strength to fiber posts with various surface treatments. *Journal of Dental Sciences* 2014, vol 9, Issue 4, 320-327
 13. Alireza Eshghi, Maryam Khoroushi. Evaluation of Three Restorative Techniques for Primary Anterior Teeth with Extensive Carious Lesions: A 1-year Clinical Study. *Journal of dentistry for children* 2013, 80(2): 80-7.
 14. Stefanie Amend, Kyriaki Seremidi, Dimitrios Kloukos, Katrin Bekes, Roland Frankenberger, Sotiria Gizani, and Norbert Krämer. Clinical Effectiveness of Restorative Materials for the Restoration of Carious Primary Teeth: An Umbrella Review. *J Clin Med*. 2022; 11(12): 3490.
 15. Fabricio Eneas Diniz de Figueiredo, Paulo Martins, André Luis Faria-e-Silva. Do Metal Post-retained Restorations Result in More Root Fractures than Fiber Post-retained Restorations? A Systematic Review and Meta-analysis. *Journal of Endodontics* 2014, 41(3) 309-316.
 16. Aashwini Lamichhane, Chun Xu, Fu-qiang Zhang. Dental fiber-post resin base material: a review. *J Adv Prosthodont*. 2014; 6(1): 60–65.
 17. Elisa Bru, Leopoldo Forner, Carmen Llana, and Amelia Almenar. Fiber post behaviour prediction factors. A review of the literature. *J Clin Exp Dent* 2013; 5(3): e150–e153.
 18. Shim JS, Kang JK, Jha N, Ryu JJ. Polymerization mode of self-adhesive, dual-cured dental resin cements light cured through various restorative materials. *J Esthet Restor Dent* 2017; 29:209–4.
 19. Gitanjali Singh. Resin based core build up materials - A review. *I P Indian Journal of Conservative and Endodontics* 2019, 4(3): 79-82.
 20. Wingo K. A review of dental cements. *J. Vet. Dent*. 2018; 35:18–27.
 21. Paulo César Freitas Santos-Filho. Effects of threaded post placement on strain and stress distribution of endodontically treated teeth. *Brazilian Oral Research* 2013. 27(4): 305-10.
 22. Bouillaguet S, Troesch S, Wataha JC, Krejci I, Meyer JM, Pashley DH. Microtensile bond strength between adhesive cements and root canal dentin. *Dent Mater*. 2003; 19(3): 199–205.
 23. Pirani C, Chersoni S, Foschi F, Piana G, Loushine RJ, Tay FR, et al. Does hybridization of intraradicular dentin really improve fiber post retention in endodontically treated teeth. *J Endod*. 2005; 31(12): 891–894.
 24. Goracci C, Fabianelli A, Sadek FT, Papacchini F, Tay FR, Ferrari M. The contribution of friction to the dislocation resistance of bonded fiber posts. *J Endod*. 2005; 31(8): 608–612.
 25. Narasimha Jayanthi and V. Vinod. Comparative Evaluation of Compressive Strength and Flexural Strength of Conventional Core Materials with Nanohybrid Composite Resin Core Material an in Vitro Study. *J Indian Prosthodont Soc*. 2013 13(3): 281–289.
 26. Yuzugully B, Ciftci Y, Saygili G, Canay S. Diametrical tensile and compressive strength of several core materials. *J Prosthet Dent*. 2008; 17: 102–107.
 27. Love R, Purton D. The effect of serrations on carbon fibre posts, retention within the root canal, core retention and post rigidity. *Int J Prosthet Dent* 1996; 9: 484–485.
 28. Akkayan B, Gulmez T. Resistance to fracture of endodontically treated teeth restored with different post systems. *J Prosthet Dent* 2002; 87: 431–437.
 29. Maccari P, Conicao E, Nunes M. Fracture resistance of endodontically treated teeth treated with three different prefabricated esthetic posts. *J Esthet Restor Dent* 2003; 15: 25–31.
 30. Purton D, Payne J. A comparison of carbon fibre and stainless-steel root canal posts. *Quintessence Int* 1996; 27: 93–97.