

ASSESSMENT OF ANTERIOR MAXILLARY ALVEOLAR BONE DIMENSIONS AND MORPHOLOGY FOR IMMEDIATE IMPLANT PLANNING: A RETROSPECTIVE STUDY USING PLANMECA PROMAX CBCT UNIT

Dina F. Ahmed* and Dina M. El Beshlawy**

ABSTRACT

Objectives: To evaluate the dimensions and morphology of the alveolar bone in the maxillary central, lateral and canine regions and to correlate these findings with the age and gender of each subject to provide detailed information for immediate implant planning.

Subjects & methods: 112 CBCT scans of both genders with non-extracted maxillary right central, lateral and canine were obtained from the database of the Oral and Maxillofacial Radiology Department, Faculty of Dentistry, Cairo University. For each of the three right maxillary anterior teeth bone height was measured from the crest of the ridge till the nasal floor. The bone width was measured at three levels, namely the cervical, the middle and the apical level. The presence and depth of buccal undercuts was also assessed at the three locations. Additionally, the cross-sectional morphology of the alveolar ridge was determined and classified into three different types.

Results: The results of this study showed that the bone height at the right central incisor had the least values; meanwhile the canine had the greatest values. Regarding the bone width, the region of the lateral incisor had the thinnest alveolar ridge at the three levels. In all the three locations however, the alveolar width was greater apically than cervically. Besides, the lateral incisor region showed the highest prevalence for presence of buccal undercuts. The greatest depth of buccal undercut however was found in the canine region, meanwhile the smallest depth was found in the central incisor region. For the cross-sectional morphology, Type I (bell-shape) was the most common in all three locations while Type III (hourglass-shape) was the least common. Age did not affect any of the examined parameters. Males showed more height and width of the alveolar bone, while females showed higher prevalence and greater depth of buccal undercuts in all three locations. Males also showed a greater prevalence of Type I (bell-shape) cross-sectional alveolar bone shape, meanwhile females showed a greater prevalence of Type II (trapezoid-shape) and Type III (hourglass-shape).

KEY WORDS: anterior maxilla, CBCT, implant, alveolar bone dimensions, buccal undercut

* Lecturer of Oral and Maxillofacial Radiology, Faculty of Dentistry, Cairo University.

** Associate Professor of Oral and Maxillofacial Radiology, Faculty of Dentistry, Cairo University.

INTRODUCTION

Long-term success of dental implants with good aesthetics in an area of primary aesthetical concern is desired by both patients and clinicians.¹ Restoring maxillary anterior region with implant-supported prostheses has been described to be a complicated procedure because of the various local risk factors and high aesthetic expectations and demands of the patients.^{2, 3} Additionally, the alveolar ridge in the anterior maxilla is narrower and has thinner cortical plates than the posterior region. Therefore, an essential determinant during implant planning in this region is to consider the amount of bone loss as this loss may have great clinical implications.^{2, 4}

The dimensional changes after tooth extraction often result in loss of bone height especially the facial alveolar plate after implant installation.⁵ As a result, an increased probability of mucosal recession and discoloration may result from the resorption of the bone in this region.^{6, 7} To avoid such complications, the use of immediate implants was suggested.⁸ Unfortunately, some clinical findings demonstrated that immediate implant placement did not prevent facial bone resorption.^{9, 10} Furthermore, the prevalence of fenestrations and dehiscences have been correlated to a thin alveolar bone.¹⁰ Several studies even suggest that after implant site preparation, the facial plate of bone thickness should not measure less than 2 mm to allow proper soft tissue support and to avoid resorption of the facial plate of bone.^{11, 12} If this cannot be achieved, then bone augmentation is suggested in order to achieve an adequate contour of bone.¹² However, this procedure implements more invasive techniques and requires more time and money as well as risks the patient is willing to accept in order to obtain the best possible aesthetic outcomes.

In addition, some studies believe that not only the available alveolar bone height determines the success of the dental implant, but also the alveolar bone width and shape. Insufficient alveolar bone width may also affect the selection of implant

length or even prohibit the use of dental implant.¹³ However, till present there are only scarce information about the alveolar bone dimensions and shape in the aesthetic zone of the maxilla.¹⁴ Only the thickness of the facial bone wall was previously investigated in many studies.¹⁵⁻¹⁷

Cone-beam computed tomography (CBCT) has been increasingly used in the dental field for its numerous advantages that include the relatively low dose of radiation and cost compared to conventional CT. CBCT also provides the ability to view a detailed three-dimensional image of the area of interest as well as submillimeter accuracy for linear measurements.¹⁸ Furthermore, it is well known that CBCT is more sensitive than conventional radiographic techniques in identifying sites of initial bone resorption.¹⁹ Moreover, CBCT may contribute to evaluate some possible pre- or post-surgical soft and hard tissue complications following implant surgery that can affect the long-term success of the dental implants.²⁰

On the other hand, Panoramic radiographs, usually used for initial planning of dental implants, tend to overestimate the available bone due to its inherent magnification.²¹ This overestimation of the size of dental implant may result in an increased possibility of injury to the adjacent vital structures. Correa et al²², showed that implant sizes estimated by CBCT images are narrower and shorter than those obtained from panoramic images, and that CBCT is a safer method. It is now believed that accurate information on the cortical and cancellous bone shape and dimensions in the aesthetic zone of the maxilla is the key to successful dental implantation in this region.²³

Therefore, the aim of this study was to evaluate the dimensions and morphology of the alveolar bone in the maxillary central, lateral and canine regions and to correlate these findings with the age and gender of the subjects in order to provide detailed information for immediate implant planning.

MATERIAL AND METHODS

This study was conducted on 112 CBCT scans (336 teeth) (35 males and 77 females) obtained from the database available at the Oral and Maxillofacial Radiology Department, Faculty of Dentistry, Cairo University. All patients were referred for a CBCT examination for different diagnostic purposes other than the purpose of this study. For a precise CBCT scans recruitment process, a predetermined list of inclusion and exclusion criteria was set:

The inclusion criteria included: Subjects of both genders, their age range was limited between 16 and 58 years (mean= 36.25) and the presence of maxillary right central, lateral and canine teeth was mandatory.

On the other hand, scans with periapical or lateral inflammatory lesions or those showing mal-alignment or with large restorations or root canal treatment related to the studied teeth were excluded. Moreover, scans with distorted images at the maxillary right anterior region or those showing an alveolar bone loss related to the studied teeth greater than or equal to 3 mm from the CEJ were left out.

CBCT scans were acquired by Planmeca Pro-Max 3D Mid machine (Helsinki, Finland). In order to standardize the imaging technique, all scans have been taken with the same parameters: 90 kVp, 8m A and 0.4 mm voxel size. The acquired images were processed and analyzed with the Romexis Viewer 4.5.0.R on a personal computer running Microsoft Windows 10 (Microsoft Corp, Redmond, WA, USA).

Measurements

The measurements of the selected cases were performed by two experienced Oral and Maxillofacial Radiologists. Each of the two investigators assessed half of the scans independently and was free to adjust any of the software image enhancement tools.

After the slice thickness adjustment on 0.4 mm, an axial cut at the mid-level of the crowns of each of the examined teeth was selected. The sagittal line was then adjusted on the axial cut to pass through the long axis of the examined tooth and perpendicular to the alveolar ridge. Measurements were performed on corrected sagittal cuts that show the entire tooth from the incisal edge till the root apex as well as the nasal floor.

For each of the three right maxillary anterior teeth (central incisor, lateral incisor, and canine), the following measurements were obtained according to the recommendations of Zhang et al.²⁴

1- Alveolar bone height

To measure the alveolar bone height, a line was drawn from the level of the alveolar crest to the floor of the nasal cavity parallel to the long axis of alveolar ridge.

2- Alveolar bone width

The alveolar width was measured, as the distance between buccal and palatal cortical plates, at three levels: cervical, middle, and apical. To perform these measurements, the alveolar height was divided into three equal parts. (Fig. 1)

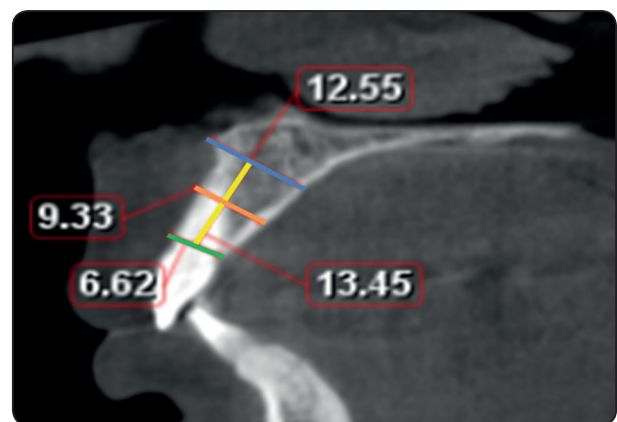


Fig. (1) Sagittal cut showing the measurements of alveolar bone height (yellow) and bone width at the cervical, middle and apical levels (green, orange and blue lines respectively)

3-Buccal undercut presence and depth

Presence or absence of buccal undercut was assessed for each examined tooth on the corresponding corrected sagittal cut. In cases where buccal undercut was present; a tangent line to the buccal cortex and parallel to the long axis of alveolar ridge was drawn. The depth of the undercut was measured from the deepest point of the undercut to this tangent line. (Fig.2)

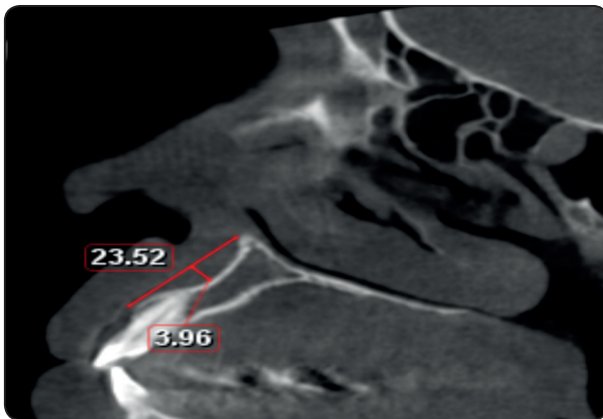


Fig. (2) Sagittal cut showing the measurement of the buccal undercut depth related to maxillary right lateral incisor

4-Cross-sectional alveolar ridge morphology

After taking the measurements, the investigators innovated a method to assess the cross-sectional morphology of the alveolar ridge at each of the three examined locations.

Type I (bell-shape): cervical < middle < apical (> 0.5mm difference)

Type II (trapezoid-shape): (cervical = middle) (< 0.5mm difference) < apical **Type III (hour-glass-shape):** middle < cervical & apical (> 0.5mm difference) .

Statistical analysis

Data were collected, revised, coded and entered to the Statistical Package for Social Science (IBM SPSS) version 23. The quantitative data were presented as means, standard deviations and ranges when their distribution was found parametric. Also, qualitative variables were presented as number and percentages. The comparison between groups regarding qualitative data was done by using Chi-square test while the comparison between two independent groups with quantitative data and parametric distribution was performed by using Independent t-test whereas the comparison between more than two independent groups with quantitative data and parametric distribution was performed by using One Way ANOVA followed by post hoc analysis using LSD test. Pearson correlation coefficients were used to assess the correlation between two quantitative parameters in the same group. The confidence interval was set to 95% and the margin of error accepted was set to 5%. The p-value was considered significant as the following: [> 0.05: Non-significant (NS), < 0.05: Significant (S) and < 0.01: Highly significant (HS)]

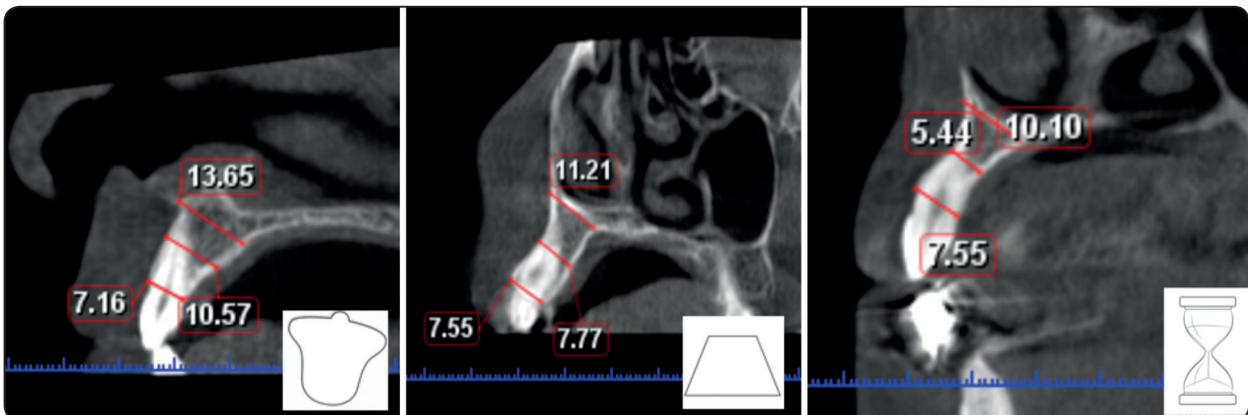


Figure 4: Type I (bell shape)

Type II (trapezoid shape)

Type III (hourglass shape)

RESULTS

The sample consisted of 112 subjects (35 males & 77 females) with age range 16-58 years and a mean age of (36.25 ± 11.23) years).

Regarding the alveolar bone height, the mean values for the maxillary right central incisor, lateral incisor and canine were: 16.76 ± 2.83 , 17.91 ± 2.65 and 18.24 ± 2.77 mm respectively. The maxillary right canine showed the greatest alveolar bone height followed by the right lateral incisor while the bone height at the right central incisor showed the least values. Upon comparing the three examined locations, a highly significant difference in the alveolar bone height was found. However, there was no statistically significant difference in the alveolar bone height between the right canine and the right lateral incisor. For the cervical width, the mean values for the maxillary right central incisor, lateral incisor and canine were 7.28 ± 0.73 , 6.79 ± 0.83 and 8.44 ± 1.15 . There was also a highly significant difference between the three examined teeth concerning the cervical alveolar bone width. Regarding the middle alveolar width, the mean values for the examined teeth were 8.72 ± 1.43 , 7.44 ± 1.30 and 8.83 ± 1.34 respectively. Here too, there was a highly statistically significant difference between the three examined locations. For the apical width, the mean values for the examined teeth were 14.43 ± 2.70 , 13.52 ± 2.38 and 14.37 ± 2.85 respectively. Again, there was a significant difference between the three examined sites.

For all the three examined locations, the alveolar width was greater apically than cervically with the maxillary canine region showing the highest values among the examined regions. Conversely, the lateral incisor regions showed the thinnest alveolar ridge at all three levels with a highly statistically significant difference from the other two locations. On the other hand, the mid and apical alveolar bone widths of the central incisor and canine regions demonstrated no statistically significant difference between them.

From the three examined teeth regions, 80.4% of right lateral incisors, 52.7% of canines and 47.3% of the central incisors had buccal undercuts. Regarding the buccal undercut depth, the mean values for the maxillary right central incisor, lateral incisor and canine were 1.02 ± 0.54 , 1.19 ± 0.58 , and 0.73 ± 0.88 respectively. There was a highly statistically significant difference between the three examined locations regarding the buccal undercut depth. The greatest depth of buccal undercut was found in the canine region.

For the cross-sectional alveolar bone morphology, Type I (bell-shape) was the most common in all three locations and appeared in 76.8% of right central incisors, 52.7% of lateral incisors, and 41.1% of canines. Type II (trapezoid-shape) appeared only in 14.3% of right central incisors, 26.8% of lateral incisors and 30.4% of canines. Type III (hourglass-shape) was the least common and appeared only in 8.9% of right central incisors, 20.5% of lateral incisors, and 28.6% of canines. For cross-sectional morphology, there was also a highly significant difference between the three examined locations. However, there was a non-statistically significant difference in the cross-sectional morphology between the lateral incisor and canine. (**Table 1**)

Regarding the correlation between age and all the examined parameters, this study showed no statistically significant difference between the different ages and all examined parameters (**Table 2**). However, for the correlation between gender and the alveolar height and width, there was a highly statistically significant difference between males and females concerning the parameters of all the examined locations. Males showed greater height and width values of the alveolar bone in the three investigated sites. In addition, there was a statistically significant difference between males and females regarding the presence of buccal undercut in all the examined locations with a higher prevalence of buccal undercuts in females.

However, there was no statistically significant difference regarding the presence of buccal undercuts between males and females in the lateral incisor region. For the buccal undercut depth, there was also a highly statistically significant difference between males and females in all three locations. Females showed greater buccal undercut depth in both lateral and canine regions. However, there was no statistically significant difference between

both genders regarding the buccal undercut depth in the canine and lateral incisor region. Furthermore, there was also a statistically significant difference between males and females regarding the cross-sectional alveolar bone morphology with males showing greater percentage of Type I (bell-shape) while females showing greater percentage of Type II (trapezoid-shape) and Type III (hourglass-shape) in all examined locations. (Table3)

TABLE (1) Comparison between the three locations in all examined parameters

		Right Canine	Right lateral incisor	Right central incisor	Test value	P-value	Sig.
		No. = 112	No. = 112	No. = 112			
Alveolar height	Mean±SD	18.24 ± 2.77	17.91 ± 2.65	16.76 ± 2.83	9.045	0.000	HS
	Range	13.68 – 26.52	10.56 – 24.64	9.44 – 24.06			
Cervical width	Mean±SD	8.44 ± 1.15	6.79 ± 0.83	7.28 ± 0.73	94.886	0.000	HS
	Range	6.09 – 12.32	5.01 – 9.9	5.44 – 9.12			
Mid width	Mean±SD	8.83 ± 1.34	7.44 ± 1.30	8.72 ± 1.43	36.177	0.000	HS
	Range	6.11 – 12.9	4.25 – 10.56	5.69 – 16.12			
Apical width	Mean±SD	14.37 ± 2.85	13.52 ± 2.38	14.43 ± 2.70	4.113	0.017	S
	Range	8.1 – 26.15	7.69 – 20.66	9.1 – 22.22			
Presence of buccal undercut	Negative	53 (47.3%)	22 (19.6%)	59 (52.7%)	29.370	0.000	HS
	Positive	59 (52.7%)	90 (80.4%)	53 (47.3%)			
Buccal undercut depth	Mean+SD	0.73 ± 0.88	1.19 ± 0.58	1.02 ± 0.54	12.961	0.000	HS
	Range	0.4 – 4.0	0.4 – 3.12	0.4 – 3.12			
Morphology	I	46 (41.1%)	59 (52.7%)	86 (76.8%)	31.071	0.000	HS
	II	34 (30.4%)	30 (26.8%)	16 (14.3%)			
	III	32 (28.6%)	23 (20.5%)	10 (8.9%)			
Post hoc analysis							
Parameters		P-value ¹		P-value ²		P-value ³	
Alveolar height		0.366		0.000		0.002	
Cervical width		0.000		0.000		0.000	
Mid width		0.000		0.560		0.000	
Apical width		0.018		0.852		0.011	
Presence of buccal undercut		0.000		0.423		0.000	
Buccal undercut depth (numeric)		0.000		0.003		0.024	
Morphology		0.189		0.000		0.001	

P1: Right canine vs Right lateral

P2: Right canine vs Right central

P3: Right lateral vs Right central

TABLE (2) Correlation between age and all examined parameters at the three locations

		Age		Test value	P-value	Sig.
		R	p-value			
Alveolar height		-0.075	0.168			
Cervical width		-0.067	0.219			
Mid width		-0.033	0.546			
Apical width		-0.027	0.622			
Buccal undercut depth		0.055	0.435			

		Age		Test value	P-value	Sig.
		Mean \pm SD	Range			
Presence of buccal undercut	Negative	35.81 \pm 12.2	16 – 58	0.587	0.558	NS
	Positive	36.54 \pm 10.53	16 – 58			
Morphology	I	36.84 \pm 11.15	16 – 58	0.570	0.569	NS
	II	34.54 \pm 11.71	16 – 58			
	III	36.6 \pm 10.73	16 – 58			

TABLE (3) Correlation between gender and all examined parameters at the three locations

		Females	Males	T e s t value	P-value	Sig.
		No. = 230	No. = 106			
Alveolar height	Mean \pm SD	17.33 \pm 2.93	18.30 \pm 2.44	2.976	0.003	HS
	Range	9.44 – 26.52	12.17 – 23.62			
Cervical width	Mean \pm SD	7.38 \pm 1.10	7.77 \pm 1.22	2.964	0.003	HS
	Range	5.01 – 12.32	5.66 – 11.52			
Mid width	Mean \pm SD	7.97 \pm 1.35	9.11 \pm 1.50	6.917	0.000	HS
	Range	4.25 – 11.81	5.4 – 16.12			
Apical width	Mean \pm SD	13.55 \pm 2.34	15.31 \pm 2.97	5.866	0.000	HS
	Range	7.69 – 20.51	8.25 – 26.15			
Presence of buccal undercut	Negative	83 (36.1%)	51 (48.1%)	4.377	0.036	S
	Positive	147 (63.9%)	55 (51.9%)			
Buccal undercut depth	Mean \pm SD	1.26 \pm 0.67	1.05 \pm 0.52	2.236	0.0046	HS
	Range	0.4 – 4	0.47 – 2.53			
Morphology	I	119 (51.7%)	72 (67.9%)	7.756	0.021	S
	II	61 (26.5%)	19 (17.9%)			
	III	50 (21.7%)	15 (14.2%)			

DISCUSSION

Nowadays in implantology, CBCT has good reputation as regards to the image quality as well as the accuracy for linear measurements at lower radiation exposure compared to conventional CT.²⁵ The alveolar bone morphology and dimensions prior to extraction may give an estimation about the available bone and therefore may help in the prediction of the prognosis of the implantation procedure.²⁶ This can also help in proper planning to obtain the best treatment outcome with maximum preservation of the adjacent bone.¹³ In this respect, the alveolar bone dimensions prior to extraction have gained importance. Particularly challenging is the anterior region of maxilla because of the high aesthetic demands and expectations of the patients.² Immediate²⁷ or early²⁸ implant procedures in this area became therefore especially attractive for the patients.

Several studies investigated the thickness of the anterior maxillary facial bone wall^{15, 16, 17} as it is frequently thin due to the facial position of the maxillary anterior teeth.²⁹ These studies reported that the facial wall may undergo considerable amount of resorption after tooth extraction. However, only limited studies investigated the overall alveolar bone shape and dimensions in this region. Therefore, this study aims to determine the dimensions and morphology of the alveolar ridge in the anterior maxilla because of its extreme aesthetic importance.

In this study, the maxillary canine region showed the greatest alveolar bone height followed by the lateral incisor while the bone height at the central incisor showed the least values. This is logic since the maxillary canine is longer than both central and lateral incisors and is the farthest from the nasal floor. Considering the alveolar bone width (apical, mid, cervical) of alveolar bone, the current study reported the thinnest apical width in the lateral incisor region; this is probably because

of the presence of the lateral fossa which creates an undercut in this region. Similar findings were also reported by Zhang et al²⁴, who stated that the maxillary lateral incisor region showed the least alveolar bone width. Panjnoush et al³⁰ also reported that the concavity in the maxillary lateral incisor region makes the ridge thinner in this area.

For the same reason, buccal undercuts were found to be most common in the lateral incisor region (80.4%) followed by the maxillary canine regions (52.7%) and were least common in the central incisor regions (47.3%). Likewise, Zhang et al, 2015²⁴ reported that the lateral incisors showed the highest incidence of presence of buccal undercuts (77%). However, they reported higher incidence of buccal undercuts in the central incisor region (41%) than the maxillary canine region (33%). Similarly, Panjnoush et al³⁰ reported the presence of concavity in the maxillary lateral incisor and canine region. Clinically, it is important to determine the presence of such undercuts as these undercuts increase the possibility of perforation of the cortical plates during implant placement procedures with subsequent serious complications and then, may also dictate the need for grafting and/or off-axial placement of the implant fixture.³¹ Detailed radiographic evaluation to avoid the aforementioned complications is highly recommended prior to implant placement in the anterior maxilla. Therefore, based on these results, extra care is recommended to be taken during implant placement in the maxillary lateral incisor region as it shows the thinnest alveolar bone as well as the highest incidence of presence of buccal undercuts. Bone grafts and modification of the surgical procedures might be commonly needed in this region.

Regarding the depth of the buccal undercuts, the results of this study showed that the canine regions had the deepest undercuts followed by the central and lateral incisors regions. These results were different from those of Zhang et al, 1015²⁴ who stated that the buccal undercut was deepest in

the lateral incisor regions, followed by the central incisors and that the least depth was found in the maxillary canine region. It is worth mentioning that in their study they reported shallower buccal undercuts and the difference in the buccal undercut depth between the three examined locations was quite smaller than the current study. This discrepancy might be due to their relatively smaller sample size and ethnic background of the patients investigated. Panjnoush et al³⁰ however, stated that the buccal concavity depth and angle of maxillary lateral and canine regions were greater in value than those reported by Zhang et al, 2015²⁴ and closer to the results of this study.

During the assessment procedure, the investigators noticed that the cross-sectional morphology of the maxillary anterior alveolar ridge could have either a shape of a bell, a trapezoid or an hourglass. This innovated classification may facilitate the connection between the clinicians and help in proper decision making. Regarding the alveolar bone cross-sectional morphology, this study showed that Type I (bell-shape) was the most common among all the examined regions. The greatest percentage was found in the maxillary central incisor region followed by the lateral incisor and the least percentage was found in the canine region. Type II (trapezoid-shape) was the second most common shape and was more common in the canine followed by the lateral incisor and least common in the central incisor regions. Type III (hourglass-shape) on the other hand was the least common in all three locations and here too, it was more common in the canine than both the lateral incisor and central incisor regions. Although there is no similar classification in the literature, Zhang et al, 2015²⁴, reported that in the maxillary anterior region, the width of the alveolar bone increases from the coronal to the apical direction and that the ridge in this region makes a bell curve-shape. Their results are still somehow similar to what we found as Type I (bell-shape) in which the alveolar bone

width increases from coronal to apical direction, was the most common type in all examined locations. Considering the aesthetic importance of the maxillary anterior region, more studies are needed to accurately assess the morphology of the alveolar ridge in this area because of its important clinical significance and its effect on the implant treatment outcomes.

Another interesting finding is that there was no correlation between the different age groups and all examined parameters in all examined locations. Our results thus meet those of Panjnoush et al³⁰ who stated that there is no significant relationship between the concavity depths in maxilla and the subject's age.

Males, on the other hand, showed higher values for the alveolar bone height and width in all three locations. These results came in agreement with Zhang et al²⁴, who reported that males demonstrated significantly greater dimensions for the alveolar ridge in the maxillary anterior region. Likewise, Braut et al²⁶ stated that in the posterior mandible the alveolar ridge is wider in males than females. Alsaffar et al, 2016³² also reported that the thickness of labial and lingual alveolar bone was greater in males than in females in both the apical and the middle thirds locations. As stated by Braun et al.³³, and Usui et al³⁴, males have thicker bone as they have heavier biting forces and stronger masticatory muscles.

Additionally, this study showed that males showed less probability to have a buccal undercut than females especially in the canine region. Males also showed less depth for the buccal undercut in the maxillary canine and lateral incisor regions. However, in the central incisor region males showed increased undercut depth than females. In total, males showed significantly less buccal undercut depth than females. However, Panjnoush et al³⁰, reported that that gender did not affect the concavity depth in both mandible and maxilla. This discrepancy may be attributed to the difference

in the method they used for measuring the buccal undercut where they did not measure the undercut from the tangent line. Parnia et al ³⁵, and Quirynen et al ³⁶ also did not state that there is a difference between both genders regarding the undercut depth. However, the latter two studies were examining the undercuts in the mandible and not maxilla. In addition, this study showed that Type I (bell-shape) alveolar bone shape is significantly more in males than females. Although the classification used here was not used before, these results were similar to those of Zhang et al ²⁴, who reported that the alveolar ridge in the maxillary anterior region increases apically and that males demonstrated significantly greater dimensions for the alveolar ridge in this region. Also, Braut et al ²⁶ reported that the alveolar ridge is wider in males than females in the posterior mandible. It is important to mention that this type of ridge which increases from coronal to apical direction is more favorable for the ease of implant placement. Females on the contrary showed significantly higher incidence of Type II (trapezoid-shape) and Type III (hourglass-shape) alveolar bone shape which are more challenging for implantologists.

CONCLUSIONS

In the anterior maxillary region, central incisors have the least alveolar bone height while lateral incisors have the thinnest alveolar bone width at the cervical, middle and apical levels. Buccal undercuts are common in the anterior maxillary region especially the lateral incisor region but are the deepest in the canine region. Type I (bell-shape) cross-sectional alveolar bone shape is the most common shape in all three locations. Males showed greater alveolar bone height and width than females, while females showed greater possibility to have buccal undercuts with greater depth. Males also showed higher prevalence of Type I (bell-shape) alveolar bone shape which is more favorable for implant insertion.

REFERENCES

1. Lang N.P., Berglundh T, Mayfield H, Pjetursson B, Salvi G. & Sanz M. Consensus statements and recommended clinical procedures regarding implant survival and complications. *The International Journal of Oral and Maxillofacial Implants (Supplement)* 2004; 19:150–154.
2. Buser D, Martin W, Belser UC. Optimizing esthetics for implant restorations in the anterior maxilla: anatomic and surgical considerations. *Int J Oral Maxillofac Implants* 2004; 19 Suppl: 43-61.
3. Rodriguez AM, Rosenstiel SF. Esthetic considerations related to bone and soft tissue maintenance and development around dental implants: report of the Committee on Research in Fixed Prosthodontics of the American Academy of Fixed Prosthodontics. *J Prosthet Dent* 2012; 108:259-67.
4. Bernard JP, Schatz JP, Christou P, Belser U, Kiliaridis S. Long-term vertical changes of the anterior maxillary teeth adjacent to single implants in young and mature adults. A retrospective study. *J Clin Periodontol* 2004; 31:1024-8.
5. Araujo, M.G. & Lindhe, J. Dimensional ridge alterations following tooth extraction. An experimental study in the dog. *Journal of Clinical Periodontology* 2005; 32:212–218.
6. Chen, S.T. & Buser, D. Clinical and esthetic outcomes of implants placed in postextraction sites. *The International Journal of Periodontics and Restorative Dentistry* 2009; 24(Suppl.):186–217.
7. Chen, S.T., Darby, I.B. & Reynolds, E.C. A prospective clinical study of non-submerged immediate implants: clinical outcomes and esthetic results. *Clinical Oral Implants Research* 2007; 18:552–562.
8. Paolantonio M, Dolci M, Scarano A, d'Archivio D, Placido G, Tumini V & Piatelli A. Immediate implantation in fresh extraction sockets. A controlled clinical and histological study in man. *Journal of Periodontology* 2001; 72: 1560–1571.
9. Sanz M, Cecchinato D, Ferrus J, Pjetursson E B, Lang NP & Lindhe J. A prospective, randomized-controlled clinical trial to evaluate bone preservation using implants with different geometry placed into extraction sockets in the maxilla. *Clinical Oral Implants Research* 2010; 21: 13–21.
10. Botticelli D, Berglundh T & Lindhe J. Hard-tissue alterations following immediate implant placement in extraction sites. *Journal of Clinical Periodontology* 2004a; 31: 820–828.

11. Buser D, Martin WD, Belser UC. Surgical considerations with regard to single-tooth replacements in the esthetic zone: Standard procedure in sites without bone deficiencies. In: Buser D, Belser U, Wismeijer D (eds). *ITI Treatment Guide, Vol 1: Implant Therapy in the Esthetic Zone—Single-Tooth Replacements*. Berlin: Quintessence, 2006:26–37.
12. Belser UC. Replacement of an upper left persisting deciduous canine with a regular neck implant, restored with a ceramometal crown, horizontally screw retained. In: Buser D, Belser U, Wismeijer D (eds). *ITI Treatment Guide, Vol 1: Implant Therapy in the Esthetic Zone—Single-Tooth Replacements*. Berlin: Quintessence, 2006:159–177.
13. Eufinger H, König S, Eufinger A. The role of alveolar ridge width in dental implantology. *Clin Oral Investig*. 1997; 1(4):169–77
14. Huynh-Ba G, Pjetursson BE, Sanz M, Cecchinato D, Ferrus J, Lindhe J, et al. Analysis of the socket bone wall dimensions in the upper maxilla in relation to immediate implant placement. *Clin Oral Implants Res* 2010; 21:37–42.
15. Ramón Fuentes, Tania Flores, Pablo Navarro1, Carlos Salamanca, Víctor Beltrán, Eduardo Borie. Assessment of buccal bone thickness of aesthetic maxillary region: a cone beam computed tomography study. *J Periodontal Implant Sci* 2015; 45:162–168.
16. Zekry A, Wang R, Chau ACM, Lang NP. Facial alveolar bone wall width -a cone-beam computed tomography study in Asians. *Clin. Oral Impl. Res.* 2014; 25: 194–206.
17. Marjan Ghassemian, Hessam Nowzari, Carlo Lajolo, Fernando Verdugo, Tommaso Pirroni, Antonio D'Addona. The Thickness of Facial Alveolar Bone Overlying Healthy Maxillary Anterior Teeth. *J Periodontol* 2012; 83:187–197.
18. González-Martín O, Oteo C, Ortega R, Alandez J, Sanz M, Veltri M. Evaluation of peri-implant buccal bone by computed tomography: an experimental study. *Clin Oral Implants Res*. Forthcoming 2015.
19. Alqerban A, Jacobs R, Fieuws S, Willems G. Comparison of two cone beam computed tomographic systems versus panoramic imaging for localization of impacted maxillary canines and detection of root resorption. *Eur J Orthod* 2011;33:93–102.
20. Nowzari H, Molayem S, Chiu CH, Rich SK. Cone beam computed tomographic measurement of maxillary central incisors to determine prevalence of facial alveolar bone width =2 mm. *Clin Implant Dent Relat Res* 2012;14:595–602.
21. Choi YG, Kim YK, Eckert SE, Shim CH. Cross-sectional study of the factors that influence radiographic magnification of implant diameter and length. *The International journal of oral & maxillofacial implants* 2004; 19(4):594–6.
22. Correa LR, Spin-Neto R, Stavropoulos A, Schropp L, da Silveira HE, Wenzel A. Planning of dental implant size with digital panoramic radiographs, CBCT generated panoramic images, and CBCT cross-sectional images. *Clinical oral implants research* 2014; 25(6):690–5.
23. Miyamoto I, Tsuboi Y, Wada E, Suwa H, Iizuka T. Influence of cortical bone thickness and implant length on implant stability at the time of surgery-clinical, prospective, biomechanical, and imaging study. *Bone* 2005; 37:776–80.
24. Zhang W, Skrypczak A, Weltman R. Anterior maxilla alveolar ridge dimension and morphology measurement by cone beam computerized tomography (CBCT) for immediate implant treatment planning. *BMC Oral Health* 2015; 15:65.
25. Sun Z, Smith T, Kortam S, Kim DG, Tee BC, Fields H. Effect of bone thickness on alveolar bone height measurements from cone-beam computed tomography images. *Am J Orthod Dentofacial Orthop* 2011;139:e117–27.
26. Braut V, Bornstein MM, Lauber R, Buser D. Bone dimensions in the posterior mandible: a retrospective radiographic study using cone beam computed tomography. Part 1—analysis of dentate sites. *The International journal of periodontics & restorative dentistry* 2012; 32(2):175–84.
27. Chen ST, Darby IB, Reynolds EC, Clement JG. Immediate implant placement postextraction without flap elevation. *J Periodontol* 2009; 80:163–172.
28. Buser D, Chen ST, Weber HP, Belser UC. Early implant placement following single tooth extraction in the esthetic zone: Biologic rationale and surgical procedures. *Int J Periodontics Restorative Dent* 2008; 28:441–451.
29. Nevins M, Camelo M, De Paoli S, et al. A study of the fate of the buccal wall of extraction sockets of teeth with prominent roots. *Int J Periodontics Restorative Dent* 2006; 26:19–29.
30. Panjnoush M, Eil N, Kheirandish Y, Mofidi N, Shamshiri AR. Evaluation of the concavity depth and inclination in jaws using CBCT. *Caspian J Dent Res* 2016; 5: 17–23.
31. Chan HL, Benavides E, Yeh CY, Fu JH, Rudek IE, Wang HL. Risk assessment of lingual plate perforation in posterior mandibular region: a virtual implant placement study

- using cone-beam computed tomography. *J Periodontol.* 2011; 82(1):129-35.
32. Alsaffar ZJ, Shafshak SM, Shokry SM. Assessment of labial and palatal alveolar bone thickness and height in maxillary anterior teeth in Saudi population using cone-beam computed tomography. *Int J Contemp Dent* 2016; 1-6.
33. Braun S, Hnat WP, Freudenthaler JW, Marcotte MR, Höni-
gle K, Johnson BE. A study of maximum bite force during
growth and development. *Angle Orthod* 1996; 66:261-4.
34. Usui T, Uematsu S, Kanegae H, Morimoto T, Kurihara S.
Change in maximum occlusal force in association with max-
illofacial growth. *Orthod Craniofac Res* 2007; 10:226-34.
35. Parnia F, Fard EM, Mahboub F, Hafezeqoran A, Gavgani
FE. Tomographic volume evaluation of submandibular
fossa in patients requiring dental implants. *Oral Surg Oral
Med Oral Pathol Oral Radiol Endod* 2010; 109:e32-6.
36. Quirynten M, Mraiwa N, Van Steenberghe D, Jacobs R.
Morphology and dimensions of the mandibular jaw bone
in the interforaminal region in patients requiring implants
in the distal areas. *Clin Oral Implants Res* 2003; 14:280-5.