

## **DETERMINATION OF MAXILLARY ANTERIOR TEETH WIDTH FOR A COMPLETELY EDENTULOUS PATIENT: PART II 3ASAL METHODOLOGY**

Safa'a Al-Sayed Asal\*

### ***ABSTRACT***

One of the most perplexing aspects of complete denture prosthodontics is the selection of appropriate maxillary anterior denture teeth size, particularly when no pre-extraction records are available. Despite the fact that the use of interalar distance, interpupillary distance, as well as distance between the medialis angles of the eyes are considered, to some extent, a reliable guide for determining the size of the maxillary anterior teeth, the literature on dentistry does not recommend one crucial method. This study is the second part of a series of research papers focusing mainly on the determination of maxillary anterior teeth width for a completely edentulous patient. The aim of the series is to suggest a new methodology for determining the maxillary anterior teeth mesiodistal width, based on certain stable guides that were derived from dentate casts with angle class I arch relationship and normal teeth alignment. These guides include basically the AB (the distance measured from the mesio-incisal angles of the maxillary central incisors along the midline and perpendicular to the intercanine (IC) line) mean distance obtained from the first study, the midline of the palate, and the arch form.

### **INTRODUCTION**

The face tends to grab most attention in social communication. It is the first thing that distinguishes a person's identity. It can be argued that the esthetic effect of dentures is the most imperative reason behind denture approbation. In fact, the size and form of the maxillary anterior teeth are quite important not only for dental esthetics but also for facial esthetics. After all, the main goal behind denture approbation is to restore the harmony between the maxillary anterior teeth and the facial

semblance. However, the dental literature does not provide a definite guide for determining the proper size and position of anterior teeth<sup>1</sup>.

Various modalities have been proposed for selecting the appropriate size of the anterior teeth,<sup>2-12</sup> though none of them have received consensus as to the accuracy in giving precise measurements for the maxillary anterior teeth size. The first paper of this series, however, reported the distance from the mesio-incisal angles of the maxillary central incisors along the midline and perpendicular to the

\* Assistant Professor, Prosthodontic Department, Faculty of Dentistry, Tanta University, Egypt.

IC line is  $9.88 \pm 0.90$ ,  $10.55 \pm 0.93$ , and  $7.73 \pm 0.63$  mm for ovoid, tapering and square arch forms respectively with significant differences between the distances and its corresponding arch forms<sup>13</sup>. Based on the fact that the loss of jaw bone after extraction reduces the size of the middle and lower thirds of the face, which is already reduced by aging as documented in the literature<sup>14-19</sup>, the Grave et al study reported that the mean distance from the labial surface of maxillary incisors to the posterior border of incisive papilla for the group with artificial teeth is significantly smaller than that for the group with natural teeth<sup>20</sup>. Hence, the author prefers to define the AB distance at 10 mm, 9 mm, 7 mm for tapering, ovoid and square arch forms respectively.

## METHODOLOGY

Determination of the mesiodistal width for the maxillary central incisors follows these procedures:

- 1- Prepare the master cast before jaw relationship record: determine and draw the midline of the maxillary cast and extend it posteriorly onto the base of the cast (Fig. 1).
- 2- Contour the facial surface of the maxillary occlusion rim intra-orally until a natural and pleasing position of the upper lip is obtained when viewed from the frontal and profile aspects.




Fig. (1) The palatal midline is drawn and extended onto the base of the cast.

- 3- Mark the midline of the face on the labial surface of the maxillary occlusion rim.
- 4- Complete the adjustment of the upper record block in a conventional manner.
- 5- Seat the maxillary record block on to the maxillary cast.
- 6- Measure 10, 9, or 7 mm for tapering, ovoid and square arch forms respectively from the labial aspect of the occlusion rim along the midline of the record block (Fig. 2).
- 7- Mark the measured distance mesially and distally on the occlusion rim, in a coronal plan and perpendicular to the palatal midline, indicating the tips of the maxillary canines (Fig. 3).
- 8- Measure the distance between the distal marks on a curve, using a flexible ruler, representing the mesiodistal width between canine cusp tips of the maxillary anterior teeth (Fig. 4).
- 9- Add 6 mm to the measurements above (the sum of canine distal slopes)<sup>21</sup>. Note that the mesiodistal width of the maxillary anterior teeth = mesiodistal width between canine cusp tips (measured labially on a curve) + 6 mm.
- 10- Complete the jaw relation record as usual.

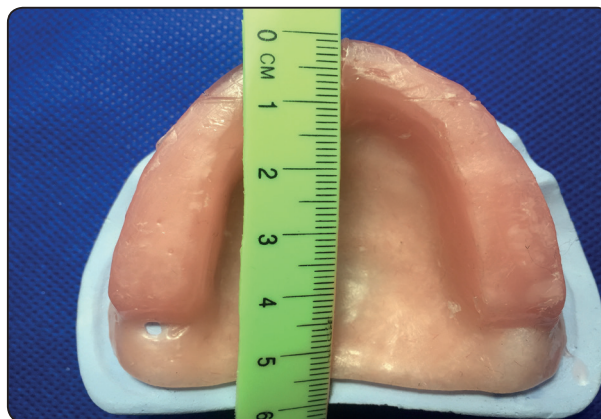

Fig. (2) Measuring the recommended AB distance from the labial aspect of the occlusion rim along the midline according to arch form

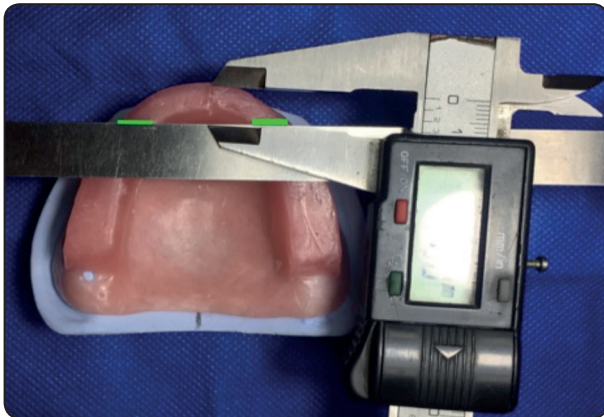


Fig. (3) Corresponding to the measured AB distance, in a coronal plan and perpendicular to the palatal midline, mesial and distal marks are dropped on the occlusion rim indicating the canine cusp tips' position.

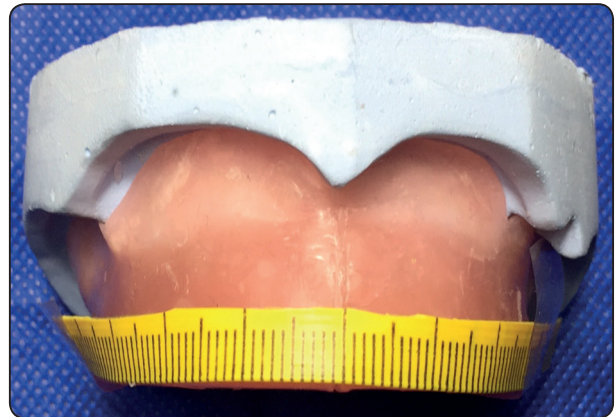


Fig. (4) Measuring the distance between the distal marks on the labial curve, using flexible ruler.

## DISCUSSION

Optimal esthetic combined with adequate renewed function is the main goal aimed at by complete denture, which highlights the significance of the size and form of the maxillary anterior teeth since it affects mainly the overall look and acceptance of the denture. Many studies had been conducted in order to contrive a guide for selection and positioning of the maxillary anterior teeth. However, most studies were conducted on youth subjects within the second decade of life, in an attempt to record idealism. It should be noted that the youthful face is characterized by a diffuse, balanced distribution of superficial and deep fascia<sup>14,15</sup>. Complete denture construction, however, is mostly related to old age subjects who have been undergoing an aging process. Of course, many changes of the face accompany aging. According to Albert et al and Rhodes, facial aging is mainly attributed to bone movement, growth and skin related deformations including the introduction of wrinkles, the reduction of fat and muscle strength<sup>16,17</sup>. In addition, the effects of aging on the face would include an increase in lip length<sup>18</sup> and thinning of the upper lip<sup>19</sup>. In the same line, the loss of jaw bone after extraction reduces the size of the middle and lower thirds of the face and makes the forehead, nose and mouth more pronounced.

Consequently, the use of facial biometric measurements taken from youth subjects may not be adequate to be applied, with precision, on edentulous subjects for the determination of maxillary anterior teeth width. In other words, for edentulous subjects, setting the maxillary anterior teeth in its original position or in the neutral zone may not be adequate enough to provide the proper lip support characterizing the measurements taken from youthful subjects. The reliability of the current methodology will not be affected by the differences between youthful measurements and those required and applied for the edentulous subjects. Previous studies have relied on facial anatomical landmarks of youth subjects, which unfortunately, undergo dramatic changes due to aging. These changes cast doubt on the applicability of these measurements with precision on old people. This is documented in the dentistry literature in relation to the conflicts between authors regarding the ratio and measurements of the used landmarks<sup>11,12,20,22,23</sup>. However, the current methodology, which relies on obtaining the proper lip support clinically, can be considered a guide for the positioning of the maxillary central incisors and determination of the mesiodistal width of the maxillary anterior teeth in different arch forms. The reliability of this

methodology is evidence based on the study of Heartwell (1984) who reported that the positions of teeth in dentulous situations usually follow the form and shape of the arch and that the arch shape would not be altered or destroyed by atrophy, resorption, accident, or surgery<sup>24</sup>. This methodology will enable the dental technician, without even seeing the patient, to determine the proper size of the maxillary anterior teeth, on the properly contoured facial surface of the maxillary occlusion rim, via applying the distances of 10, 9, 7 mm according to the arch form (as mentioned throughout this study). It should be noted, however that the technician has to commit to the contouring of maxillary occlusion rim obtained clinically. Finally, this will help reduce the clinical time of both the dentist and the patient.

## REFERENCES

- Hasanreisoglu U, Berksun S, Aras K, Arslan I. An analysis of maxillary anterior teeth: facial and dental proportions. *J Prosthet Dent.* 2005; 94:530-8.
- Hoffman W Jr, Bomberg TJ, Hatch RA. Interlar width as a guide in denture tooth selection. *J Prosthet Dent.* 1986; 55:219-21.
- Mavroskoufis F, Ritchie GM. Nasal width and incisive papilla as guides for the selection and arrangement of maxillary anterior teeth. *J Prosthet Dent.* 1981; 45: 592-7.
- Faure JC, Rieffe C, Maltha JC. The influence of different facial components on facial esthetics. *Eur J Orthod.* 2007; 13: 609–13.
- Clapp GW. How the science of esthetic tooth form selection was made easy. *J Prosthet Dent.* 1955; 5: 598-608.
- Krajicek DD. Natural appearance for the individual denture patient. *J Prosthet Dent* 1960;10: 205-14.
- Gomes VL Gonçalves LC, Costa MM, Lucas Bde L. Interlar distance to estimate the combined width of the six maxillary anterior teeth in oral rehabilitation treatment. *J Esthet Restor Dent.* 2009; 21: 26–36.
- Hall WR. Shapes and sizes of teeth in American system of dentistry. Lea Bros and co, Philadelphia. 1887; p 971.
- Wehner PJ, Hickey JC, Boucher CO. Selection of artificial teeth. *J prosthet dent.* 1967; 18: 222–32
- Lee JH. Dental esthetics: The pleasing appearance of artificial dentures. John Wright and Sons, Ltd, Bristol. 1962
- Ehrlich J, Gazit E. Relationship of the maxillary central incisors and canines to the incisive papilla. *J Oral Rehabil.* 1975; 2: 309-12.
- Grove HF, Christensen LV. Relationship of the maxillary canines to the incisive papilla. *J Prosthet Dent.* 1989; 61: 51-3.
- Asal SA. Determination of maxillary anterior teeth width for a completely edentulous patient: part I comparative study in dentate arab subjects with different arch forms. *EDJ* 2017; 63: 1-7.
- Donofrio LM. Fat distribution: a morphologic study of the aging face. *Dermatol Surg.* 2000; 26:1107-12.
- Little JW. Volumetric perceptions in midfacial aging with altered priorities for rejuvenation. *Plast Reconstr Surg.* 2000; 105: 252-66.
- Albert AM, Ricanek K, Patterson E. A review of the literature on the aging adult skull and face: implications for forensic science research and applications. *Forensic Sci Int.* 2007; 172: 1-9.
- Rhodes MG. Age estimation of faces: a review. *Appl Cogn Psychol.* 2009; 23; 1–12.
- Kaur M, Garg KR, Singla S. Analysis of facial tissue changes with aging and their effects on facial morphology: A forensic perspective. *Egyptian Journal of Forensic Science* 2015; 5:46-56.
- Sforza DC, Binelli MG, De Menezes MC, Ferrario V. Age and sex-related changes in three-dimensional lip morphology. *Forensic Sci Int.* 2010; 200: 1-7.
- Grave A. M.H, Becker P.J. Evaluation of the incisive papilla as a guide to anterior tooth position. *J Prosthet Dent.* 1987; 57: 712-14.
- Scheid RC, Weiss G. Woelfel's Dental Anatomy, 8<sup>th</sup> ed., Wolters Kluwer 2012, p83.
- McGee GF. Tooth placement and base contour in denture construction. *J Prosthet Dent.* 1960; 10: 651-7.
- Solomon EGR, Arunachalam KS. The Incisive Papilla: A Significant Landmark in Prosthodontics. *J Indian Prosthodont Soc.* 2012; 12: 236–47.
- Heartwell CM Jr. . Syllabus of complete denture, 3<sup>rd</sup> edn. Lea & Febiger, Philadelphia. 1984; pp 330–42.