EGYPTIAN DENTAL JOURNAL

Vol. 64, 3467:3484, October, 2018

I.S.S.N 0070-9484

Oral Medicine, X-Ray, Oral Biology and Oral Pathology

www.eda-egypt.org • Codex : 189/1810

THE TOPICAL APPLICATION EFFECT OF NANO-HYDROXYAPATITE VERSUS PLATELET RICH FIBRIN ON THE EARLY STAGES OF EXTRACTION SOCKET HEALING IN RABBITS: HISTOMORPHOMETRIC, HISTOCHEMICAL AND IMMUNOHISTOCHEMICAL STUDY

Rabab Hassan* and Khaled El-Sayed El-Haddad*

ABSTRACT

Introduction: The proper healing of extraction socket is essential for ridge preservation and better sequential prosthetic procedures. Several techniques and materials are developed for acceleration of socket healing. Two of the promising materials for this purpose are nanohydroxyapatite (NHA) and platelet rich fibrin (PRF); their mechanism of action and optimum application techniques are still not fully elucidated.

Purpose: To compare between NHA and PRF topical application in the enhancement of early stages of extraction socket healing in rabbits.

Materials & Methods: The mandibular first molars were extracted in twenty-four rabbits; the extraction sockets were divided into 3 groups: control group didn't receive topical treatment. N and P groups received topical application of NHA and PRF respectively. Each group was subdivided into 2 subgroups according to the date of scarification after extraction: 1 week and 2 weeks. The extraction sockets were investigated by hematoxylin and eosin (H&E), Masson trichrome (MT) stains and proliferation cell nuclear antigen (PCNA) marker. The results were illustrated histologically and histomorphometrically.

Results: Both NHA and PRF treated groups in both 1 week and 2 weeks periods showed enhanced socket healing, more regular and mature bone in both H&E and MT stains as well as increased PCNA positive cells percentage in comparison to control group. The bone area in both periods and the osteocyte count after 1 week were highest in PRF group followed by NHA group while control group revealed the least values. These differences were statistically non-significant except the percentage of immuno-positive cells.

Conclusion: Both NHA and PRF improve the extraction socket healing process with slight preference of PRF particularly in the cellular proliferation in the first week after extraction.

KEYWORDS: Nanohydroxyapatite, platelet rich fibrin, Extraction socket.

* Lecturer, Department of Oral Biology, Faculty of Dentistry, Ain Shams University.

INTRODUCTION

Tooth extraction sockets are the most frequent wounds created in the head and neck region[1]. Extraction socket healing is a complex and sequential process targeting to maintain normal anatomical structure and function [2-4]. When the healing of extraction wound studied histologically it showed a complex cascade of biological events including migration of osteoprogenitor cells and subsequently differentiation towards specific cell lineages, cell proliferation, revascularization and formation of extracellular matrix [5, 6]. One of the most important challenges is the preservation of the residual alveolar ridge after extraction, that will aid in the future successful implant placement and promote rehabilitation [7].

Many techniques for ridge preservation have been proposed and studied to achieve the needed goal of performing appropriate rapid wound healing [8]. The usually used method for alveolar ridge maintenance is to fill the alveolar fossa "the socket cavity" [9, 10]. Several alveolar fossa filling materials were studied such as spongelike poly-ethyl ester/polypropylene [10], injectable calcium phosphate [11], bioactive glass [12] and collagen plug [13].

Hydroxyapatite (HA) has long been among the most studied biomaterials in the medical field for both its demonstrated biocompatibility and for being the most important element of the mineral part of bone and teeth [14]. Nanotechnology is naturally very broad, including several fields of science [15]. Nanotechnologists participates in regenerative medicine by the creation of nanostructures and biomaterials aiming at developing systems that can create and reinforce in vivo tissue repair strategies [16]. One of these biomaterials is nano-hydroxyapatite (NHA), crystals that ranging in size between 50 to 1000 nm [14]. It could be synthesized by chemical methods [17] or by a more recent method: "template technique", an important method of biomimetic synthesis using a template to manage the growth direction of the crystal and to achieve nano-apatite that has a comparable structure and components as that in the natural bone [18]. Combination with growth factors is an important approach for NHA functional transformation [19, 20]. However, growth factors are expensive and their preservation over a prolonged period is complicated, therefore, greatly restricting their clinical application [21].

Lots of researchers have focused on the use of NHA as a co-adjuvant material in oral surgery, particularly concerning the osseo-integration, osteoconductivity [22] and stimulation of cell proliferation [23]. Several studies reported that NHA presents excellent bioactivity, angiogenic properties, no toxicity, and absence of inflammatory or antigenic reactions [24]. The explanation of the NHA mechanism of regenerative capacity is chiefly due to their close composition similarity with natural bone [25, 26]. Additionally, bone tissue binds directly to HA, inducing the deposition of newly formed bone [27]. It has been confirmed that HA surface supports osteoblastic cell adhesion, growth, and differentiation [28].

Concerning the effects of HA on extraction socket healing, authors declared that HA is potentially a good bone alternate for extracted canine socket healing [29]. In oral and maxillofacial reconstruction, bovine HA represents one of the most important biomaterials for bone reconstruction for endosseous implants so far [30-32]. On the other hand, some limitations worth attention, mainly related to the high manufacturing costs [33]. Herein, much attempt has been paid for obtaining other natural sources for HA [34]. Yet, the physical and chemical properties of the nanometer apatite (crystallinity, calcium phosphate scale, etc.) and induced osteogenesis performance require more improvements [21].

Platelet rich fibrin (PRF) is the second generation of platelet concentrates subsequent to the first generation, platelet rich plasma (PRP). Preparation of PRF was first described by ***Choukroun et al.*** in 2006 [35]. Minimal operator experience is required to conduct the procedure of PRF preparation and

grafting when compared to bone harvesting from remote sites [36, 37]. The preparation process is simple and does not require any thrombin or coagulant [38]. PRF is harvested from venous blood and does not lead to immune rejection in clinical application[38, 39]. PRF has a flexible and durable three-dimensional network configuration [39] which is rich in fibrin, platelets, white blood cells, growth factors, cytokines, and other components conducive to tissue repair[39-41]. These components can be helpful in regulating the proliferation, differentiation and apoptosis of repair-related cells, and subsequently regulating and promoting tissue repair [42]. Moreover, PRF is safe, effective and more economical as a transplant material for alveolar site preservation [43].

The regenerative abilities of PRF are related to growth factors which accelerate bone repair and support fibroblast proliferation. Also, these factors increase tissue vascularity, the rate of collagen formation, and mitosis of mesenchymal stem cells, endothelial cells and osteoblasts [44]. Several authors have also verified that a fibrin matrix provides an optimal support for mesenchymal stem cells [45-47]. As a result of all these powerful effects, PRF is able to increase the quality, density and formation rate of the novel bone therefore it could be used effectively as a socket preservation aid due to the concentration of growth factors. Additionally, there are evidences supported the use of PRF to enhance soft tissue healing and diminish postoperative complications [48-50].

On the light of the above information, this study was conducted in order to compare between these two promising materials, NHA and PRF in the socket healing early stages.

MATERIALS AND METHODS

Animals and grouping

Twenty-four adult healthy male local rabbits weighing between 1.5 and 2 kg were used in this study. The experimental work was done in compliance with the bio-ethical guidelines of Ain Shams University Animal House under supervision of veterinarian. Surgical extraction of the lower first molar has been performed in all rabbits. The animals were randomly divided into 3 main groups as follows:

Control group: The mandibular right first molar was extracted, and no topical treatment was applied in the extraction socket.

Experimental groups (NHA and PRF): Right and left mandibular first molars were extracted with consequent topical application of Nano hydroxy apatite (NHA) crystal in the right-side socket and platelet rich fibrin (PRF) in the left side socket (each side of the mandible was considered a separate group). Thus, 3 separate groups were studied (control, NHA and PRF).

Each group was further subdivided into 2 subgroups according to the date of scarification (1week and 2 weeks postoperatively). Occasionally, due to animal mortality or accidental mandible fracture during operation, the left side of the control rabbits was used to compensate the lost samples in the experimental group. Table (1) illustrates the description of the groups and subgroups division as well as the number of the collected molar regions from the rabbits that survived till the end of the experiment.

Nano-hydroxyapatite powder: HA nanopowder <200 nm particle size, was in plastic container purchased from (Sigma-Aldrich Company).

PRF preparation technique

For collection of blood for PRF preparation, xylene local application for vasodilatation on ear vein then the PRF preparation was performed with guidance of the protocol reported by **Saluja et al., (2011)**. Around 2 cm of venous blood is collected in sterile vacutainer tube of 6 ml capacity without anticoagulant. The vacutainer tubes are then placed in a centrifugal machine at 3000 revolutions per minute (rpm) for 10 minutes, after which it settles

TABLE (1): Summary of groups and subgroups with the number of collected molar areas from which survived till the end of the experiment.

Groups	**Control**		**NHA**		**PRF**	
Treatment material	No topical treatment		Nanohydroxy-apatite crystal powder topical application		Platelet rich fibrin topical application	
Subgroups	C1W	C2W	N1W	N2W	P1W	P2W
Subgroups (time of scarification)	1 week	2 weeks	1 week	2 weeks	1 week	2 weeks
Sample size	5	4	6	6	7	5

into three layers: red lower fraction containing red blood cells, upper straw-colored cellular plasma and the middle fraction containing the fibrin clot. The upper straw-colored layer is removed, and middle fraction is collected, 2 mm below lower dividing line, which is the PRF. The mechanism which is followed here is that, fibrinogen which is initially concentrated in the high part of the tube, combines with the circulating thrombin due to centrifugation, to form fibrin clot in the middle of the tube [51].

Surgical extraction technique

Rabbits were subjected to general anesthesia: Ketamine (50mg/kg body weight) intravenous injection in the rabbit ear vein in addition to xylazine (5 mg/kg). For more accessibility unilateral horizontal incision of cheek was performed, then the mandibular first molar was extracted by hand instrument. After extraction, the treatment materials (NHA or PRF) were gently applied in the extraction socket in case of the experimental groups. Finally, suturing of socket, buccal mucosa and skin was performed using 2/0 sterile synthetic absorbable suture (Egysorb©). Post-operative topical antibiotic spray was applied for infection control in addition to systemic antibiotic (intramuscular injection of ceftriaxone 100mg/kg body weight once daily for 7 days) and anti-inflammatory (diclofenac sodium 15 mg/kg body weight IM twice daily for 3 days).

Sample preparation for light microscopy

After the end of experimental period of each subgroup, the mandibular molar areas were dissected and fixed immediately in 10% formalin solution for not less than five days. The samples were then decalcified by using Ethylene Diamine Tetra-acetic acid (EDTA) solution. The decalcified samples were washed properly under running water, dehydrated by transferring through increasing concentrations of alcohol, then transferred to xylol to clear the specimen from alcohol. The specimens were embedded in the center of paraffin wax blocks, sectioned by microtome (3-5 microns) in bucco-lingual direction, transferred in decreasing concentrations of alcohol ended by distilled water and processed for hematoxylin and eosin (H&E) and Masson trichrome stains. The samples were examined by light microscope (Olympus model: BX60F5 - Olympus optical co. Ltd – Japan) at magnifications (200 and 400) according to the examined structure and the measurement requirements.

For immunohistochemical examination, selected representative samples after the histological examination were processed for staining by Proliferating Cell Nuclear Antigen (PCNA) marker. The tissues were mounted on positive glass slides. The deparaffinized slides were washed two times in buffer and incubated in hydrogen peroxide block 10 minutes. Samples were then washed in buffer and incubated 5 minutes at room temperature. The primary antibody was applied then samples were incubated and washed 4 times in buffer. Primary antibody enhancer was applied and the samples were incubated for 10 minutes at room temperature and washed 4 times in buffer. Horseradish peroxidase

polymer was applied, and samples were incubated for 15 minutes at room temperature and washed 4 times in buffer. One drop (40 microliter) Diaminobenzidine DAB Plus Chromogen was added to 2 ml of (DAB) Plus substrate, mixed by swirling and applied to the tissue then incubated for 5 minutes. Samples were washed in deionized water 4 times; the slides were stained by counter stain (hematoxyline) and finally over-slipped [52, 53].

Histomorphometric analysis

The area percentage of the developed new bone was measured in the H&E stained sections of 1week subgroups, then the number of osteocytes per unit area in the woven bone was counted in three equal regions in each slide. Regarding the 2 weeks groups, the percentage of the bone area was measured in 5 equal fields in each slide. The bone area percentage was calculated in each captured field as follow: [(area of the developed bone / area of the field) x 100]. PCNA stained sections were analyzed by measuring the area percentage of the immunepositive cells in 5 regions in each slide of the one-week subgroups. All these measurements were performed via Image J software (version: 1.52f Wayne Rasband, National Institute of Health, USA). Results were statistically analyzed using one-way ANOVA test to compare between subgroups followed by Post Hoc test (pairwise comparison with Bonferroni adjustment of P value) to compare between each 2 subgroups. The difference is considered significant when P value is less than 0.05.

RESULTS

I- Histological results (H&E)

a) One week after extraction

The extraction sockets of the ***control subgroup (C1W)*** that were sacrificed 1 week after extraction revealed granulation tissue formation with hemorrhagic areas enclosing blood capillaries. In some regions, newly developed areas of bone matrix were observed connected with the old bone of the socket wall **(fig.1).** The granulation tissue consisted of collagen fibrils, cellular elements embedded in primitive connective tissue extracellular matrix. New blood capillaries lined by squamous endothelial cells and enclosed scares RBCs were observed with adjacent inflammatory cells. There were spotty areas of woven bone entrapping new osteocytes and bordered by active osteoblasts **(fig. 2).**

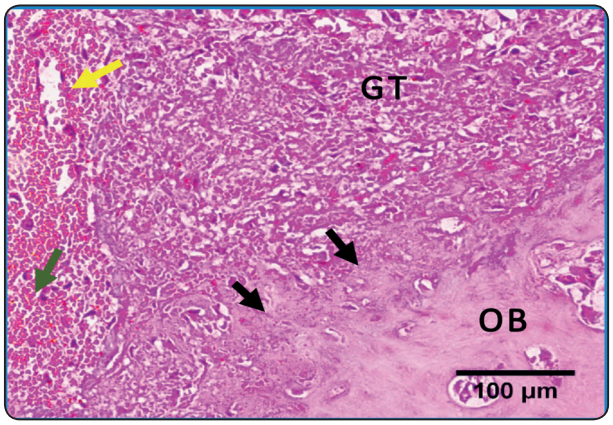

Fig. (1): Photomicrograph of (C1W) showing granulation tissue "GT", hemorrhagic areas "green arrow", blood capillary "yellow arrow", osteoid "black arrows" attached to old bone "OB" (H&E x200).

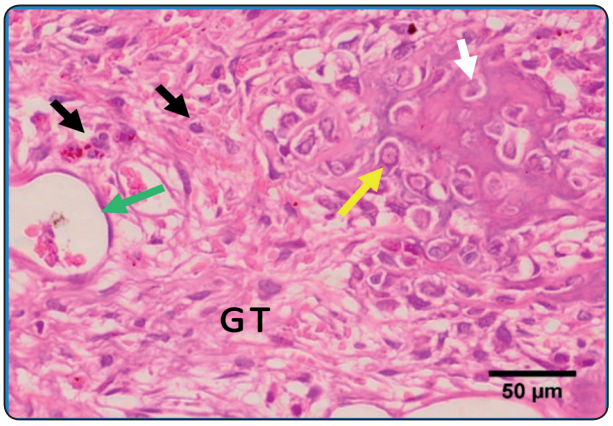

Fig. (2): Photomicrograph of (C1W) showing new blood capillaries lined by squamous endothelium containing RBCs "green arrow", inflammatory cells "black arrows" in the fibrous granulation tissue "GT" and spotty areas of woven bone enclosing osteocytes "white arrow" and bordered by active osteoblasts "yellow arrow" (H&E x400).

The extraction sockets of ***subgroup (N1W)*** presented apparent woven bone development. There were numerous osteocytes and observable marrow cavities development. Granulation tissue separates woven bone from old bone was seen**(fig.3).** Many areas showed woven bone consisted of irregular trabeculae enclosing variable size spaces which were lined by osteoblasts and enclosed well developed blood vessels. The neighboring connective tissue displayed cellular elements with irregular collagen fibrils in the extracellular material. Occasionally, empty areas of the NHA remnant spaces were detected **(fig.4).**

The examination of the extraction sockets of ***subgroup (P1W)*** revealed similar features to those in N1W subgroup, however, this subgroup was characterized by the predominance of the RBCs, the relatively more organized trabecular pattern of the woven bone which occupied more area with detectable decrease in the granulation tissue amount that separate newly formed woven bone from old bone **(fig.5).** The new bone contained numerous, variable size and shapes entrapped osteocytes and the marrow cavities were lined by osteoblasts and were rich in RBCs which occasionally were observed to infiltrate the bone matrix to be adjacent to the entrapped osteocytes **(fig.6).**

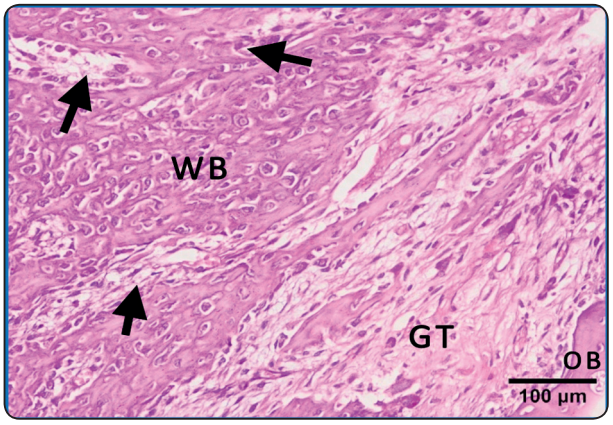

Fig. (3): Photomicrograph of (N1W) showing woven bone "WB" with developing marrow cavities "arrows". The granulation tissue "GT" separates woven bone from old bone "OB" (H&E x200).

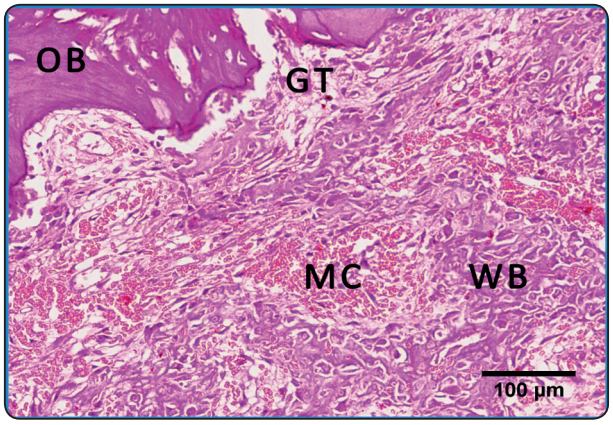

Fig. (5): Photomicrograph of (P1W) showing woven bone "WB" surrounding marrow cavities "MC" with numerous RBCs. WB is separated from old bone "OB" by granulation tissue "GT" (H&E x200).

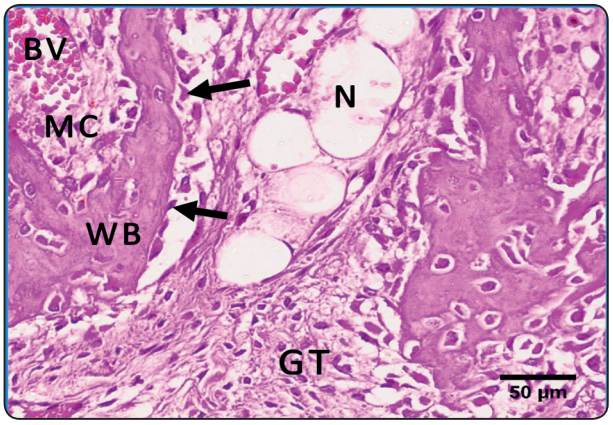

Fig. (4): Photomicrograph of (N1W) showing trabecula of woven bone "WB" enclosing marrow cavity "MC" which contains blood vessel "BV" and lined by osteoblasts "arrows". Granulation tissue "GT" showed empty areas reveal the NHA spaces "N" (H&E x400).

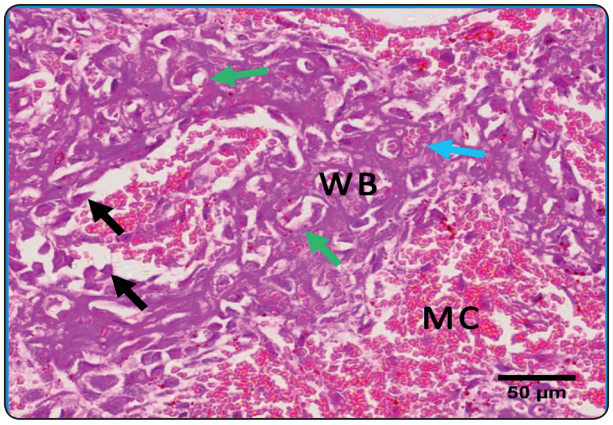

Fig. (6): Photomicrograph of (P1W) showing trabecula of woven bone "WB" with numerous osteocytes "green arrows". The marrow cavity "MC" were lined by osteoblasts "black arrows" and rich in RBCs which infiltrate the bone trabeculae "blue arrow" (H&E x400).

b) Two weeks after extraction:

The extraction sockets of the control rabbits sacrificed 2 weeks after extraction ***(subgroup C2W)*** revealed increase in the area of the developing bone and noticeable osteoblastic activity as well as vascular network establishment with considerable RBCs. However, the bone segments were often separated by fibrous connective tissue and rarely interconnected to the trabecular pattern **(fig.7).** Osteoblasts bordered the developing bone were detected, some of them showing beginning of entrapment in the lacunae. The osteocytes appeared occupied their lacunae which were wide, unorganized and close to each other. Moderate size blood vessel was observed**(fig.8).**

The subgroup (N2W) displayed clear signs of enhanced bone development forming mature lamellar bone. The trabecular pattern was established surrounding marrow cavities. The trabeculae harbored osteocytes in their lacunae which were relatively organized around the marrow cavities and widely separated by the bone matrix. Some areas showed primary osteon (Haversian system). Furthermore, resting and reversal lines were often noticed in the trabeculae **(fig.9).** The bone marrow cavities were filled with cellular elements and small blood vessels. The lining of the bone trabeculae showed massive cellular proliferation and osteoblastic activity in some regions with characteristic plump appearance of the active osteoblasts. Less frequently, osteoclasts were observed in their Howship's lacunae **(fig.10 and 11).**

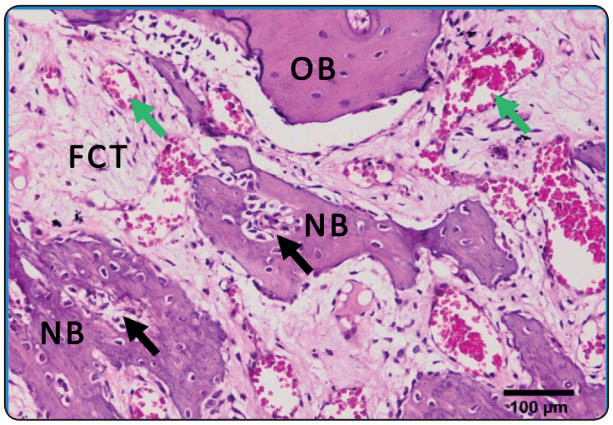

Fig. (7): Photomicrograph of (C2W) showing newly developing bone "NB" enclosing small marrow cavities "black arrows" and separated from each other and from old bone "OB" by fibrous connective tissue "FCT". Variable sizes of blood vessels are seen "green arrows" (H&E x200).

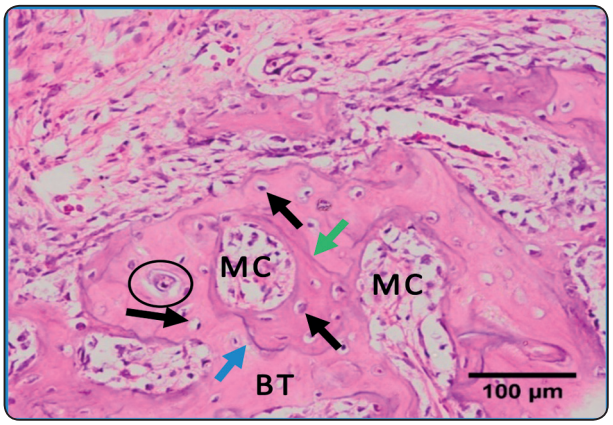

Fig. (9): Photomicrograph of (N2W) showing lamellar bone trabeculae "BT" surrounding the marrow cavities "MC" as well as primary osteon "circle". The oriented osteocyte lacunae "black arrows", resting line "green arrow" and reversal line "blue arrow" are observed (H&E x200).

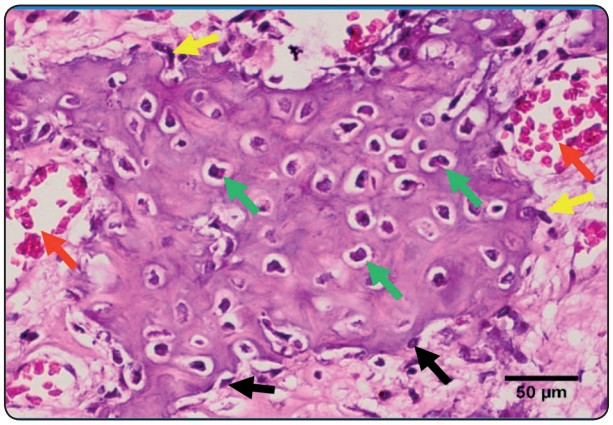

Fig. (8): Photomicrograph of (C2W) showing developing bone trabecula with randomly entrapped osteocytes in wide lacunae "green arrows". Osteoblasts outlining the bone "black arrows"; some of them showing beginning of entrapment in the lacunae "yellow arrows". Note the moderate size blood vessel "red arrows" (H&E x400).

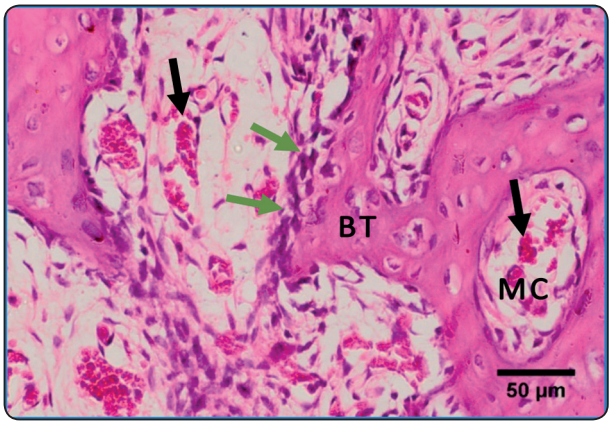

Fig. (10): Photomicrograph of (N2W) showing bone marrow cavities "MC" occupied by cellular elements and small blood vessels "black arrows". Bone trabeculae "BT" are lined by proliferating crowded osteoblasts"green arrows" (H&E x400).

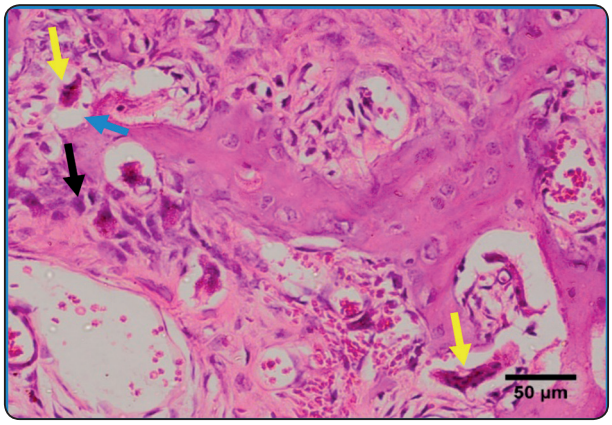

Fig. (11): Photomicrograph of (N2W) showing plump appearance of the active osteoblasts "black arrow" and osteoclasts "yellow arrows" in their Howship's lacunae "blue arrow" (H&E x400).

The histological features of the PRF treated rabbits ***(subgroup P2W)*** revealed mature lamellar bone with well-defined marrow cavities densely packed with cellular and vascular elements surrounded by thick trabeculae. Areas of compact bone were evidenced with the appearance of Haversian canals occupied by cellular elements as well as longitudinal Volkmann's canals **(fig.12).** Mature stellate shaped osteocyte were embedded and widely separated by the bone matrix,while the osteoblasts were evenly outline the bone edges in a linear manner **(fig.13).**

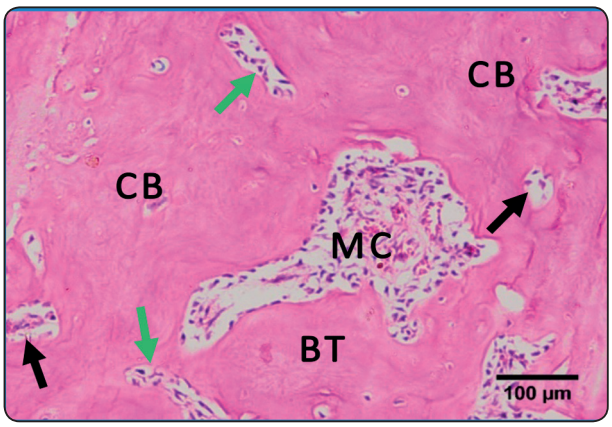

Fig. (12): Photomicrograph of (P2W) showing mature lamellar bone. Cellular marrow cavities "MC" surrounded by thick trabeculae "BT". Compact bone "CB" with Haversian canal "black arrow" and Volkmann's canals"green arrow" (H&E x200).

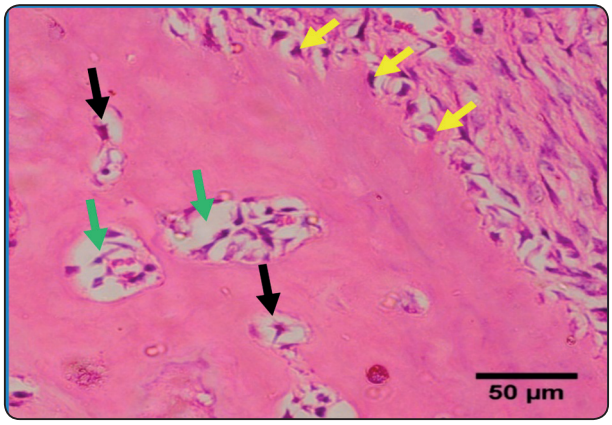

Fig. (13): Photomicrograph of (P2W) showing mature stellate shaped osteocytes "black arrows", Haversian canals "green arrows" and osteoblasts outlining the bone edge "yellow arrows" (H&E x400).

II- Histochemical results (Masson trichrome "MT")

a) One week after extraction:

Massontrichrome staining was performed to determine the deposition and arrangement of collagen secreted in the process of socket healing. The blue color was indicated to the regenerated bone, newly formed (immature) collagen fibers, or osteoid, while the red stained areas were indicated to the mature bone and old (mature) collagen.

One week after extraction, the control subgroup (C1W) showed the expression of blue color stained areas of randomly arranged immature collagen fibrils in which the newly developed bone spicules were blue stained **(fig. 14a).** In the treated rabbits, some specimens of subgroup (N1W) revealed areas of maturation (red colored) **(Fig. 14b)**, while the subgroup (P1W) showed less apparent maturation which was illustrated by spotty reddish staining in minute areas **(fig. 14c).**

b) Two weeks after extraction:

The extraction sockets of subgroup (C2W) presented minimal observed matured bone tissue only in the periphery of the bone masses **(fig. 14d).** The N2W subgroup showed more clearly observed maturation of the developing bone **(fig. 14e)** in comparison to the well- organized bone tissue of the (P2W) subgroup**(fig. 14f).**

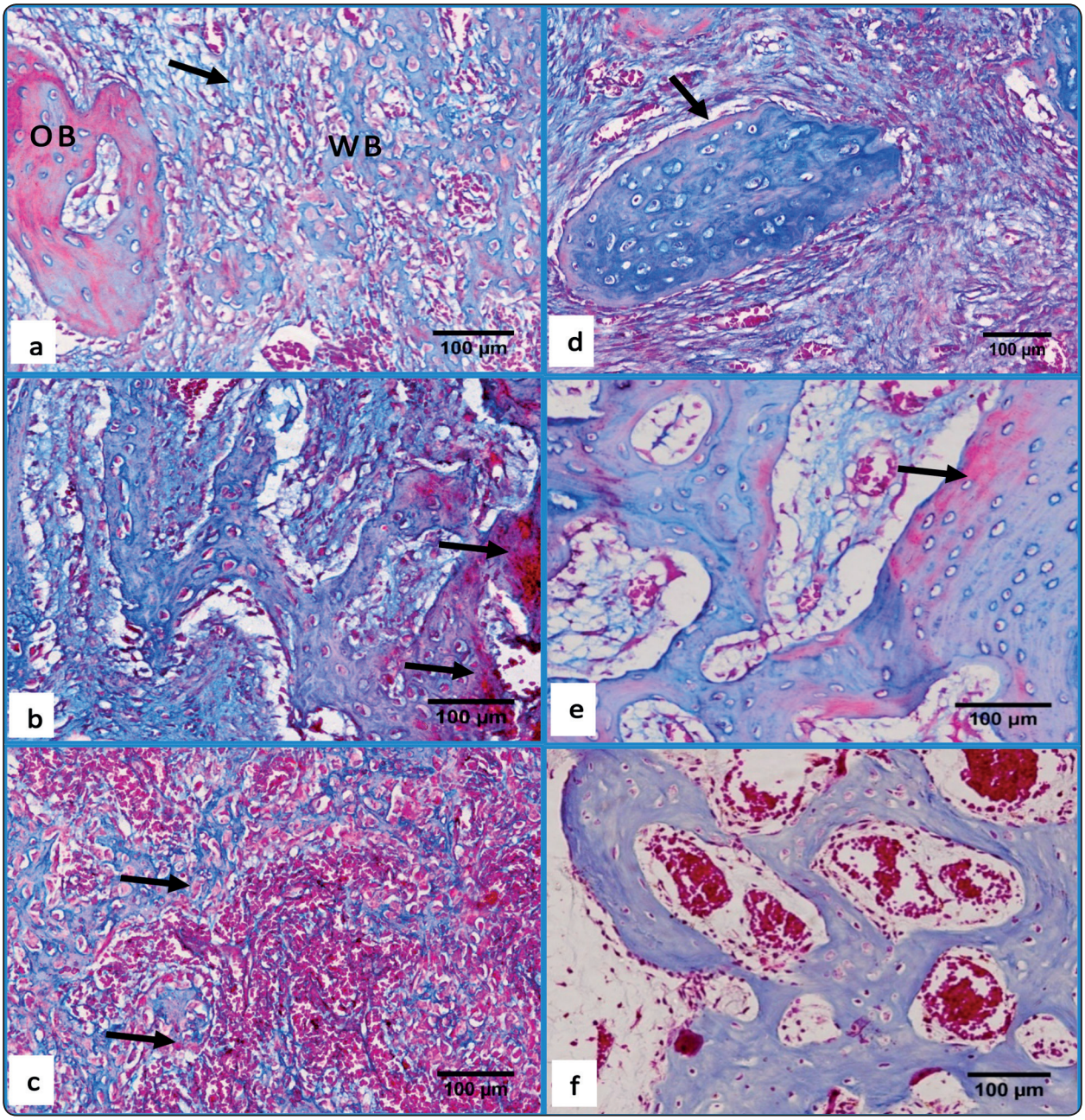

Fig. (14): Photomicrograph of control subgroup C1W (a) showing blue stained areas of randomly arranged immature collagen fibrils "arrow"and newly developed bone spicules "WB" adjacent to old bone "OB".In the treated rabbits, some specimens of subgroup N1W (b) revealed areas of maturation "arrows", while the subgroup P1W (c) showed less apparent maturation with spotty reddish staining "arrows". Subgroup C2W(d) with minimal matured bone tissue in the periphery of the bone masses "arrow". N2W subgroup "e" showing more clearly observed maturation "arrow" in comparison to the well-organized bone tissue of the P2W subgroup "f" (Masson trichrome x200).

III- Immunohistochemical results (Proliferating Cell Nuclear Antigen "PCNA"):

a) One week after extraction:

The control subgroup (C1W) showed variable reactions to PCNA marker in the granulation tissue filling the socket cavity. Few cells showed positive reaction (brown staining) with variable intensities. Occasionally, immuno-negative cells were observed **(fig.15a).** On the other hand, N1W subgroup showed predominance of the positive reaction with few cells with negative immunoreaction**(fig. 15b).** The P1W

subgroup revealed positive reactions which were concentrated in proximity to the developing bone matrix.**(fig. 15c).**

b) Two weeks after extraction:

In this period of the present study, we traced the immune reaction in the cellular lining of the bone trabeculae. The extraction sockets of subgroup (C2W)revealed negative reaction in almost all the osteoblasts lining the bone trabeculae **(fig. 15d).** On the contrary, N2W subgroup the osteoblastic reaction for PCNA was positive along the bone periphery **(fig. 15e).** While subgroup P2W showed both positive and negative stained cells**(fig. 15f).**

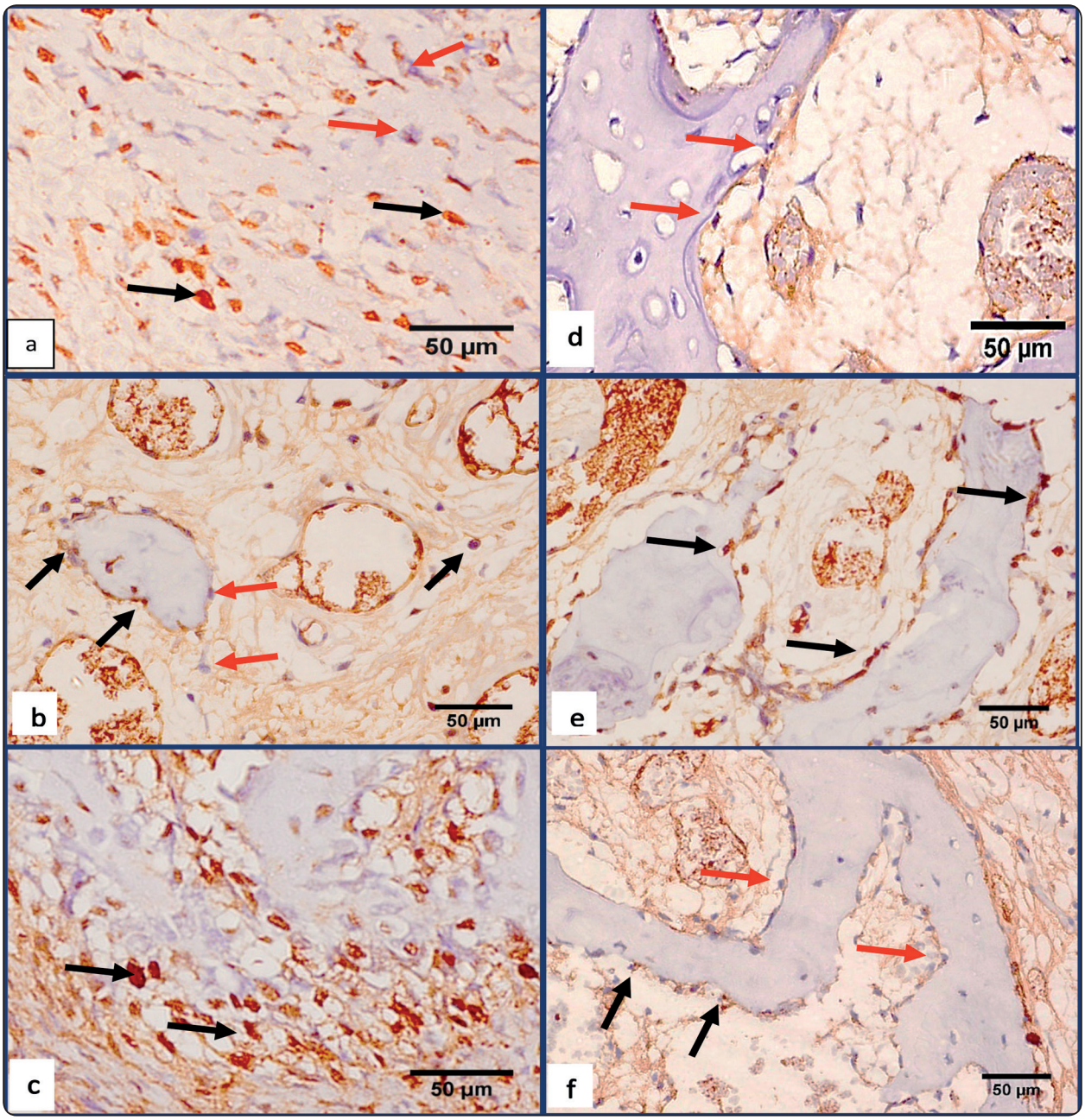

Fig. (15): Photomicrograph of C1W subgroup (a) showed few immunopositive cells "black arrows" and immuno-negative cells "red arrows". N1W subgroup (b) showed predominance of the positive reaction "black arrows" with few cells with negative immunoreaction "red arrows". The P1W group (c) revealed positive reactions "black arrows" concentrated in proximity to the developing bone matrix. Subgroup C2W (d) revealed negative reaction in almost all the osteoblasts lining the bone trabeculae "red arrows" while N2W subgroup (e) showed positive reactions along the bone periphery"black arrows". Subgroup P2W (f) showed both positive"black arrows" and negative stained cells "red arrows" (PCNA x400).

IV- Statistical results:

Four parameters were analyzed in the present work, three in the histological sections and one in the PCNA stained sections. H&E stained sections of the one-week subgroups were evaluated through measuring the new bone area percentage and the number of osteocytes per mm^2. While in the 2 weeks subgroups, the area percentage of the developed bone was measured.The PCNA stained samples were investigated regarding the area percentage of the immunopositive cells in the one-week subgroups.

In all the studied parameters the mean values of PRF subgroups revealed the highest measurements followed by NHA subgroups while the control subgroups showed the least values. The mean and standard deviation of each subgroup for all parameters are summarized in table (2& 3) and the differences between subgroups were illustrated in **(fig. 16-19).** All the differences of the parameters were statistically non-significant (P value > 0.05) except in the percentage of the immune-positive cells where ANOVA test revealed significant difference between the 3 subgroups (p <0.5). the comparison between each 2 subgroups showed that the difference between control group and PRF group was significant while the other results were statistically non-significant.

TABLE (2): The mean and standard deviation (SD) of the subgroups in different parameters of one-week duration.

	Bone area percentage		**Osteocyte per mm^2**		**Area percentage of immuno-positive cells**	
	Mean	SD	Mean	SD	Mean	SD
C1W	34.50	5.91	956.65	130.42	1.80	0.39
N1W	35.08	5.46	1051.82	266.65	4.28	0.75
P1W	44.94	8.35	1094.90	42.67	5.00	0.22

TABLE (3): Mean and standard deviation (SD) of the subgroups in bone area percentage in two-weeks duration.

	Bone area percentage (2 w)	
	Mean	SD
C2W	45.24	2.65
N2W	50.22	0.43
P2W	63.46	20.36

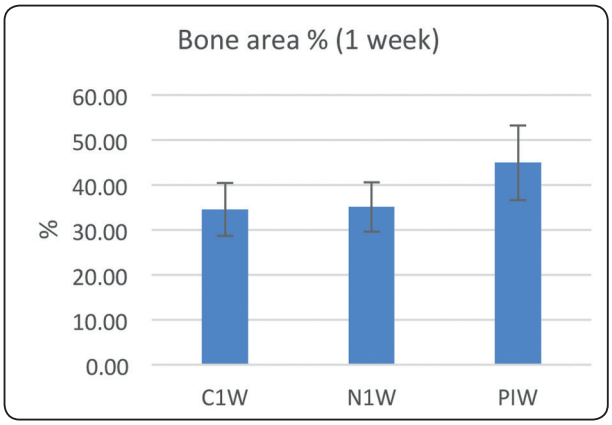

Fig. (16): Bar chart of the bone area % in 1 week.

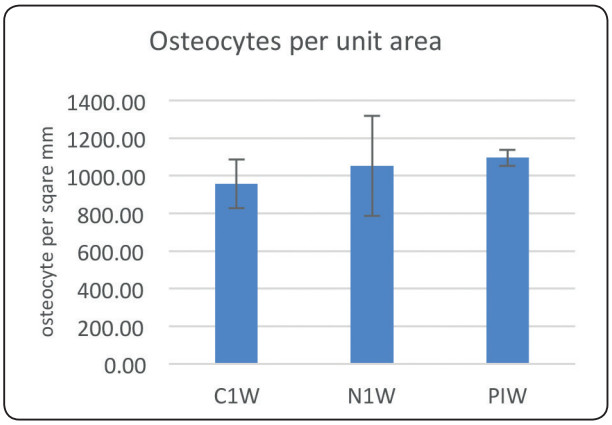

Fig. (17): Bar chart of osteocyte per unit area (1 week).

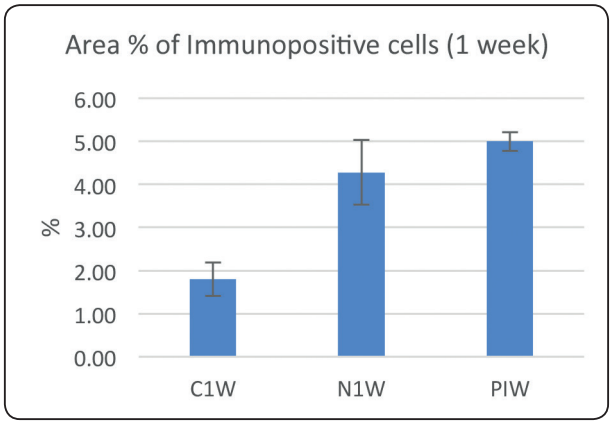

Fig. (18): Bar chart of area % of immunopositive cells (1 week).

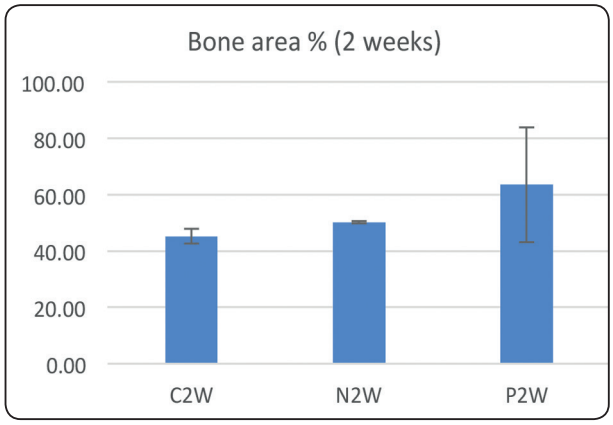

Fig. (19): Bar chart of the bone area % in 2 weeks.

DISCUSSION

Bone repair is a complex process involving cellular activities and mineralization with subsequent remodeling of the defect site to reach the original structure [54]. There are many studies have been performed for enhancement of these complex processes [55]. The ongoing study was designed to compare between the effects of two recent promising materials, nanohydroxyapatite (NHA) and platelet rich fibrin (PRF) on the extraction socket healing in rabbits. The results were compared with naturally healing tooth sockets to assess the enhancement in the healing process.

The selection of NHA powder was attributed to their widespread use in the bone regeneration procedures such as the pre-prosthetic surgery to increase the thickness of the alveolar ridge [14]. On the other hand, PRF in the membrane form was reported as one of the current methods to preserve the extraction socket and prevent ridge resorption [9]. Many authors considered PRF is the best to avoid cross-infections [37, 43] in addition to minimal required operator expertise [37].

In the current study, the investigations were focused on the early stages of socket healing, 1 and 2 weeks after extraction due to their well-known critical importance during the bone healing [56]. Furthermore, the predominance of the effects of the studied materials is directed mainly to these early stages; hydroxy-apatite was reported to cause early osteointegration around implants in the osteoporotic rabbits [57]. Nano-hydroxyapatite possesses clear influence on early bone formation [58]. Regarding PRF, it is reported that its maximal promoting effect occurred at day 14 of healing process [59].

The rabbits were preferred in the present work due to their easy handling compared with rats and mice. Besides, small rodents have primitive bone structures and do not have defined Haversian systems identical to those in humans [60] while rabbits have Haversian systems that are identical to that of human being, which is an important advantage in terms of validity of the obtained results.

The surgical procedure in the ongoing work included cheek and skin incision for easier accessibility, hence, decreasing the trauma on the alveolar bone. Besides, systemic post-operative antibiotic and anti-inflammatory drugs were administrated to avoid post-operative infections. These precautions have been taken to avoid healing impairment caused by infections or large traumatic bone defects [61]. After extraction, PRF was gently adapted to cover the socket to ensure the complete cover of the wound and to decrease the chance of displacement during suturing [62].

The investigation techniques used in the present study in addition to the routine histological examination were Masson trichrome stain and PCNA immunohistochemical marker. Masson trichrome was selected to define the deposition of new collagen in the deposited bone matrix as an indirect index of the quantity of the newly formed bone [63, 64]. While, PCNA was designated to the detect the proliferation activity which is one of the main phases in bone healing particularly in the early stages [65]. The proliferation process was expected to be predominating in the studied duration in our work, particularly one-week duration. This coincide with ***Vieira et al., (2015)*** who demonstrated high labeling of cell proliferation at seven days of bone healing process [66].

In the present study, the histological results of the first week duration revealed improvement in the healing process in both NHA and PRF treated rabbits with slight superior results in the PRF subgroups. The increased proliferative activity during the first week was monitored in both treated subgroups via statistically increased osteocytes per unit area as well as percentage of the PCNA positive cells in the PRF treated rabbits. Positive interaction between HA and mesenchymal stem cells was reported by ***Venkatesan et al., (2015)*** [67] which may explain the increased proliferation rate of the NHA treated rabbits in the current work.

The higher proliferation occurred in the PRF treated subgroup may be explained by the adhesiveness and tensile strength for clot stabilization provided by PRF thus promoting higher metabolic activity and cell proliferation[45,68]. Moreover, PRF stimulates the chemotactic migration of circulating mesenchymal stem cells to the injury site [69,70] and provide a matrix for tissue-forming cells like fibroblasts [56].

In the present work, PRF subgroup sacrificed one week after extraction showed massive vascular network with abundant RBCs. This agreed with ***Brown et al., (2015)*** who reported that fibrin is a natural guide for angiogenesis [70]. PRF can provide a matrix for migration of endothelial cells, which are involved in angiogenesis [56].

In the current study, PRF showed slight superior features over NHA specifically in the histomorphometric analysis. The activity of PRF in the first week of healing in the present study coincides with previous work demonstrated that the ingrowth, proliferation and differentiation of osteoblasts occurs during the initial 14 days with PRF treatment [71, 72]. Moreover, PRF was reported to perform certain biological effects during the first week. According to ***Knapen et al., (2015),*** connective cells could be observed in the region of the osteotomy 1 week after PRF application [73].

In the herein study, the second duration "2 weeks after extraction" revealed continuation of the healing enhancement in both NHA and PRF subgroups in comparison to the control subgroup. The bone trabecular size and maturation were noticeably progressed. However, Masson trichrome staining revealed maturation in NHA treated rabbits. This coincides with the positive effect of HA and NHA on the bone mineral density [29, 67]. Moreover, some authors demonstrated a positive effect of HA on the alkaline phosphatase activity in osteoblast cells [74, 75].

The previously mentioned osteogenic activity of NHA could explain the histological results in the present work which showed lamellar bone development and primary osteon formation as well as the positive reaction of osteoblasts to PCNA. Moreover, PRF in the two-weeks duration revealed advanced histological evidences of bone maturation represented by frequent observation of Haversian systems as well as increased bone area histomorphometrically more apparently than in NHA treated rabbits.

These findings were in accordance to ***Kim et al., (2014)*** [76] and ***Zhang et al., (2018)*** [43] who suggested that PRF can stimulate bone regeneration. Moreover, PRF was reported to increase in bone

density [36, 37]. On the contrary, ***Faot et al., (2017)*** [56] reported that the treatment of PRF application did not significantly enhance the healing dynamics except for significantly higher bone trabecular parameter after 14 days. However, the authors investigated the bone healing of a defect in rabbit tibia, a long bone, which have different rate of bone healing from the flat bone [77] as mandibular bone in the present work which might cause the conflict with our results. The authors stated that the morphology of the tibiae did not favor retention of the PRF clot during healing. Moreover, the authors investigated bone healing via micro-X-ray computed tomography analysis, and other clinical parameters which didn't include histological examination which was the basis of our study.

To our knowledge, the exact mechanism of the PRF osteogenic activity is not clearly explored. However, the gold standard for in vivo tissue healing and regeneration requires the mutual interaction between a scaffold (fibrin matrix), platelets, growth factors, leukocytes, and stem cells [78]. These key elements are all active components of PRF, and when combined and prepared properly, they will be involved in the key processes of tissue healing and regeneration, including cell proliferation and differentiation, extracellular matrix synthesis, chemotaxis and angiogenesis (neo-vascularization) [79]. Additionally, the cytokines and growth factors are integrated within the fibrin matrix and gradually released in the initial period of healing enhancing the healing process [59, 80]. Besides the mentioned biochemical bases of PRF activity, the easily applied PRF matrix acts as a fibrin bandage [81] and provides good protection of the operation site [82].

Finally, considering the positive osteogenic effects of NHA and PRF, however, PRF is more recommended in the maneuver of socket healing acceleration not only due to the reported advanced histological and immunohistochemical features, but also due to some limitations with the use of NHA especially related to the high manufacturing costs [23] compared to the simple technique and less cost of PRF [36] as well as the avoidance of cross infection [37]. The major limitation of the present study was with obtaining a statistical significance due to a limited number of survival animal included. Thus, it is recommended that a larger sample may be studied in conjunction with a detailed and more objective radiological parameters and protocols to verify the findings of this study.

CONCLUSIONS

Within the limitations of the present study, we concluded that both NHA and PRF enhances the extraction socket healing with slight advantage of PRF particularly in the first week in terms of cellular proliferation and angiogenesis. Both studied materials were comparable in healing improvement during the second week period.

REFERENCES

1. Al-Shammari, K., Al-Ansari, J. and Al-Melh, M.: Reasons for tooth extraction in Kuwait. Med PrincPract.; 15(6):417-422, 2006.
2. Vieira, A., Repeke, C., Ferreira, S., Colavite, P., Biguetti, C., Oliveira, R., Assis, G., Taga, R. and Trombone, A.: Intra-membranous Bone Healing Process Subsequent to Tooth Extraction in Mice:Micro-Computed Tomography, Histomorphometric and Molecular Characterization. PompermaierGarletPlos.; 1:15- 22, 2015.
3. Babu, K., Naik, V., Latha, J. and Prabhakar, V.: Wound healing activity of ethanolic extract of natural products (Azadirachtaindica bark) in albino Wister rats. World Journal of Pharmacy and Pharmaceutical Sciences.; 5(6):1624-1632, 2016.
4. Harshmohan, M. A.: Text Book of Pathology. Jaypee Brothers Medical Publishers. New Delhi.; p252, 2005.
5. Luginbuehl, V., Meinel, L., Merkle, H. and Gander, B.: Localized delivery of growth factors for bone repair. European Journal of Pharmaceutics and Biopharmaceutics; 58:197-208, 2004.
6. Madhan, G. and Madhumati, S.: Comparison of Ability of Platelet rich Fibrin vs Colla Plug in maintaining the Buccal Bone Height of Sockets following Extractions in 20 Patients. Journal of Health Sciences and Research; 8(1):1-6, 2017.

7. Jiing, H.Z., Chung, H.T. and Yu, C.C.: Clinical and histologic evaluation of healing in an extraction socket filled with platelet-rich fibrin. J Dent Sci.; 6:116-22, 2011.

8. Hartshorne, J. and Gluckman, H.: A comprehensive clinical review of Platelet Rich Fibrin (PRF) and its role in promoting tissue healing and regeneration in dentistry. Part II: preparation, optimization, handling and application, benefits and limitations of PRF. International Dentistry; 6:34-48, 2016.

9. Bartee, B.K.: Extraction site reconstruction for alveolar ridge preservation. Part 1: Rationale and materials selection. J Oral Implantol.; 27:18793, 2001.

10. Serino, G., Biancu, S., Iezzi, G. and Piattelli, A.: Ridge preservation following tooth extraction using a polylactide and polyglycolide sponge as space filler: A clinical and histological study in humans. Clin Oral Implants Res.; 14:651658, 2003.

11. Gauthier, O., Boix, D., Grimandi, G., Aguado, E., Bouler, J.M., Weiss, P. and Daculsi, G.: A new injectable calcium phosphate biomaterial for immediate bone filling of extraction sockets: A preliminary study in dogs. J Periodontol.; 70:375383, 1999.

12. Yilmaz, S., Efeoğlu, E. and Kiliç, A.R.: Alveolar ridge reconstruction and/or preservation using root form bioglass cones. J Clin Periodontol.; 25:832839, 1998.

13. Chan, H.L., Lin, G.H., Fu, J.H. and Wang, H.L.: Alterations in bone quality after socket preservation with grafting materials: A systematic review. Int J Oral Maxillofac Implants; 28:710-720, 2013.

14. Erlind, P., Lait, K.B., Gaspare, P., Gianluca, T. and Guido, M.: Nano-hydroxyapatite and its applications in preventive, restorative and regenerative dentistry: a review of literature.Ann Stomatol (Roma).; 5(3):108–114, 2014.

15. Saini, R., Saini, S. and Sharma, S.: Nanotechnology: The Future Medicine". Journal of Cutaneous and Aesthetic Surgery; 3(1):32–33, 2010.

16. Perán, M., García, M.A., Lopez-Ruiz, E., Jiménez. G. and Marchal, J.A.: How can nanotechnology help to repair the body, advances in cardiac, skin, bone, cartilage and nerve tissue regeneration. Materials; 6:1333-1359, 2013.

17. Sopyan, I., Pusparini, E., Ramesh, S., Tan, C.Y., Ching, Y.C., Yew, H.W., Nor, Z.A., Hari, C.T. and Bang, L.T.: Influence of sodium on the properties of sol-gel derived hydroxyapatite powder and porous scaffolds. Ceramics International; 43(15):12263–12269, 2017.

18. Stefanic, M., Krnel, K., Pribosic, I. and Kosmac, T.: Rapid biomimetic deposition of octacalcium phosphate coatings on zirconia ceramics (Y-TZP) for dental implant applications. Applied Surface Science; 258(10):4649–4656, 2012.

19. Dan, Q.U., Jihua, L.I., Yubao, L.I., Ying, G., Yi Zuo, Y., Yuchun, H. and Jing, H.: Angiogenesis and osteogenesis enhanced by bFGF ex vivo gene therapy for bone tissue engineering in reconstruction of calvarial defects. Journal of Biomedical Materials Research Part A; 96(3)543–551, 2011.

20. Feito, M.J., Serrano, M.C., Oñaderra, M., Matesanz, M.C., Sánchez, S., Arcos, D., Vallet-Regí, M. and Portolés, M.T.: Effects of immobilized VEGF on endothelial progenitor cells cultured on silicon substituted and nanocrystalline hydroxyapatites. RSC Advances.; 6(95):92586–9295, 2016.

21. Linbo, D., Yancong, Z. and Hanwen, S.: Advances in Synthesis and Functional Modification of Nanohydroxyapatite. Journal of Nanomaterials; Article ID 3106214, 2018.

22. Masahiro, Y., Takeshi, U., Naoki, T., Takayuki, I., Kaori, N., Norio, H., Takeo, S. and Takahiro, O.: Bone integration capability of nanopoyimorphic crystalline hydroxyapatite coated on titanium implants. Int J Nanomedicine; 7:859–873, 2012.

23. Kasai, A., Willershausen, B., Reichert, C., Rohring, B., Smeets, R. and Schmidt, M.: Ability of nanocrystalline hydroxyapatite paste to promote human ligament cell proliferation. J Oral Sci.; 50(3):279–285, 2008.

24. Appleford, M.R., Oh, S., Oh, N. and Ong, J.L.: In vivo study on hydroxyapatite scaffolds with trabecular architecture for bone repair. J Biomed Mater Res A,; 89:1019-1027, 2009.

25. Chaves, M.D., DeSouza, L.S., DeOliveira, R.V., Holgado, L.A., Filho, H.N., Matsumoto, M.A. and Ribeiro, D.A.: Bovine hydroxyapatite (Bio- Oss ((R))) induces osteocalcin, RANK-L and osteoprotegerin expression in sinus lift of rabbits. J Craniomaxillofac Surg.; 40:315-320, 2012.

26. Meimandi, P.A., Oryan, A.Z., Shafiei, S., Bigham, A.S.: Effectiveness of synthetic hydroxyapatite versus Persian Gulf coral in an animal model of long bone defect reconstruction. J OrthopTraumatol.; 14:259-268, 2013.

27. Kattimani, V., Lingamaneni, K.P., Chakravarthi, P.S., Kumar, T.S. and Siddharthan, A.: Eggshell-Derived Hydroxyapatite: A New Era in Bone Regeneration. J Craniofac Surg.; 27:112-117, 2016.

28. Abdel-Fattah, W.I. and Elkhooly, T.A.: Nano-beta-tricalcium phosphates synthesis and biodegradation: 2. Biodegradation and apatite layer formation on nabo-beta-TCP synthesized via microwave treatment. Biomed Mater; 5:35015, 2010.
29. Jang, S.J., Kim, S.E., Han, T.S., Son, J.S., Kang, S.S. and Choi, S.H.: Bone Regeneration of Hydroxyapatite with Granular Form or Porous Scaffold in Canine Alveolar Sockets. In Vivo; 31:335-341, 2017.
30. Schlegel, K.A., Zimmermann, R. and Thorwarth, M.: Sinus floor elevation using autogenous bone or bone substitute combined with platelet-rich plasma. Oral Surg Oral Med Oral Pathol Oral RadiolEndod.; 104:15-25, 2007.
31. Dahlin, C., Simion, M., Hatano, N.: Long-term follow-up on soft and hard tissue levels following guided bone regenerationtreatment in combination with a xenogeneic filling material: a 5-year prospective clinical study. Clin Implant Dent Relat Res.; 12:263-270, 2010.
32. Hallman, M. and Nordin, T.: Sinus floor augmentation with bovine hydroxyapatite mixed with fibrin glue and later placement of nonsubmerged implants: a retrospective study in 50 patients. Int J Oral Maxillofac Implants; 19:222-227, 2004.
33. Jones, J.R.: Reprint of: Review of bioactive glass: From Hench to hybrids. Acta Biomater.; 23:53-82, 2015.
34. Granito, R.N., Renno, A.M., Yamamura, H., de Almeida, M.C., Ruiz, P.M. and Ribeiro, D.A.: Hydroxyapatite from Fish for Bone Tissue Engineering: A Promising Approach Int J Mol Cell Med.; 7(2):80-90, 2018.
35. Choukroun, J., Diss, A., Simonpieri, A., Girard, M.O., Schoeffler,. C, Dohan, S.L., Dohan, A.J., Mouhyi, J. and Dohan, D.M.: Platelet-Rich Fibrin (PRF): A second-generation platelet concentrate. Part IV: Clinical effects on tissue healing. Oral Surg Oral Med Oral Pathol Oral RadiolEndo.; 101: 56-60, 2006.
36. El Masri, M., Shokry, M., Attia, N. and Ramal. A.: "Comparison of Prf Versus Collagen Membrane on Healing of Socket and Bone Formation (Randomized Split Mouth Design)". Acta Scientific Dental Sciences; 2 (7):13-22, 2018.
37. Srinivas, B., Das, P., Rana, M.M., Qureshi, A.Q., Vaidya, K.C. and Ahmed Raziuddin, S.J.: Wound healing and bone regeneration in postextraction sockets with and without platelet-rich fibrin. Ann Maxillofac Surg.; 8:28-34, 2018.
38. Dohan Ehrenfest, D.M: How to optimize the preparation of leukocyte and plateletrich fibrin (LPRF, Choukroun's technique) clots and membranes: Introducing the PRF Box. Oral Surg Oral Med Oral Pathol Oral RadiolEndod.; 110: 275280, 2010.
39. Dohan Ehrenfest, D.M., Del Corso, M., Diss, A., Mouhyi, J. and Charrier, J.B.: Threedimensional architecture and cell composition of a Choukroun's plateletrich fibrin clot and membrane. J Periodontol.; 81:546555, 2010.
40. Li, Q., Pan, S., Dangaria, S.J., Gopinathan, G., Kolokythas, A., Chu, S., Geng, Y., Zhou, Y. and Luan, X.: Plateletrich fibrin promotes periodontal regeneration and enhances alveolar bone augmentation. Biomed Res Int.; 638043, 2013.
41. Anitua, E., Alkhraisat, M.H. and Orive, G.: Perspectives and challenges in regenerative medicine using plasma rich in growth factors. J Control Release; 157: 2938, 2012.
42. Choukroun, J., Diss, A., Simonpieri, A., Girard, M.O., Schoeffler, C., Dohan, S.L., Dohan, A.J., Mouhyi, J. and Dohan, D.M.: Plateletrich fibrin (PRF): A secondgeneration platelet concentrate. Part V: Histologic evaluations of PRF effects on bone allograft maturation in sinus lift. Oral Surg Oral Med Oral Pathol Oral RadiolEndod.; 101: 299303, 2006.
43. Zhang, Y., Ruan, Z., Shen, M., Tan, L., Huang, W., Wang, L. and Huang, Y.: Clinical effect of platelet-rich fibrin on the preservation of the alveolar ridge following tooth extraction. Experimental and Therapeutic Medicine; 15: 2277-2286, 2018
44. Kumar, R.V. and Shubhashini, N.: Platelet rich fibrin: A new paradigm in periodontal regeneration. Cell Tissue Bank; 14:453–463, 2013.
45. Gassling, V., Douglas, T., Warnke, P.H., Açil, Y., Wiltfang, J. and Becker, S.T.: Platelet-rich fibrin membranes as scaffolds for periosteal tissue engineering. Clin. Oral Implants Res.; 21: 543–549, 2010.
46. Kang, Y.H., Jeon, S.H., Park, J.Y., Chung, J.H., Choung, Y.H., Choung, H.W., Kim, E.S. and Choung, P.H.: Platelet-rich fibrin is a Bioscaffold and reservoir of growth factors for tissue regeneration. Tissue Eng.; 17:349–359, 2011.
47. Dohan Ehrenfest, D.M., Doglioli, P., de Peppo, G.M., Del Corso, M. and Charrier, J.B.: Choukroun's platelet-rich fibrin (PRF) stimulates in vitro proliferation and differentiation of human oral bone mesenchymal stem cell in a dose-dependent way. Arch. Oral Biol.; 55:185–194, 2010.
48. Al-Hamed, F., Abdel-Monem, M.T., Abdelfadil, E.: "Clinical effects of platelet-rich fibrin (PRF) following surgical extraction of lower third molar". The Saudi Journal for Dental Research 8:19-25, 2017.

49. Singh, A., Kohli, M. and Gupta, N.: "Platelet rich fibrin: a novel approach for osseous regeneration". Journal of Maxillofacial and Oral Surgery; 11(4): 430-434, 2012.

50. Jeyaraj, P.E. and Chakranarayan, A.: Soft tissue healing and bony regeneration of impacted mandibular third molar extraction sockets, following postoperative incorporation of platelet-rich fibrin. Ann Maxillofac Surg.; 8:10-18, 2018

51. Saluja, H., Dehane, V. and Mahindra, U.: Platelet-Rich fibrin: A second generation platelet concentrate and a new friend of oral and maxillofacial surgeons Ann Maxillofac Surg.; 1(1): 53–57, 2011.

52. Shi, S.R., Guo, J., Richard, J.C., Young, L., Hawes, D., Shi, Y., Thu, S. and Clive, R.T.: Antigen retrieval technique. Applied Immunohistochemistry & Molecular Morphology. 1st edition Eaton Publisher; 7(3):201-208, 1999.

53. Ptrosyan, K., Tamayo, R. and Jouseph, D.: Sensitivity of novel Biotin Free detection reagent (Power vision+) for immunohistochemistry. J. Histotechnology; 25:247-250, 2002.

54. Oda, T., Kinshita, K. and Ueda, M.: Effect of cortical bone perforation on periosteal destruction. J. Maxillofac. Surg.; 67(7): 1478-1485, 2009.

55. Dimitriou, R., Jones, E., McGonagle, D. and Giannoudis P.: Bone regeneration: current concepts and future directions. BMC Medicine; 9:66, 2011.

56. Faot, F., Deprez, S., Vandamme, K., Camargos, G., Pinto, N., Wouters, J., van den Oord, J., Quirynen, M., and Duyck, J.: The effect of L-PRF membranes onbone healing in rabbit tibiae bone defects: micro-CT and biomarkerresults scientific reports 7: 46452, 2017.

57. Li, J.P., Li, P., Hu, J., Dong, W., Liao, N.N., Qi, M.C. and Li, J.Y.: Early healing of hydroxyapatite-coated implants in grafted bone of zoledronic acid-treated osteoporotic rabbits. J Periodontol.; 85(2):308-316, 2014.

58. Meirelles, L., Arvidsson, A., Andersson, M., Kjellin, P., Albrektsson, T. and Wennerberg, A.:Nano hydroxyapatite structures influence early bone formation. J Biomed Mater Res A.; 87(2):299-307, 2008.

59. He, L., Lin, Y., Hu, X., Zhang, Y. and Wu, H.: A comparative study of plateletrich fibrin (PRF) and plateletrich plasma (PRP) on the effect of proliferation and differentiation of rat osteoblasts in vitro. Oral Surg Oral Med Oral Pathol Oral RadiolEndod.; 108: 707713, 2009.

60. Nunamaker, D.M.: Experimental models of fracture repair. Clin OrthopRelat Res.; 355: 56–65, 1998.

61. Ensrud, K.E., Harrison, S,L., Cauley, J.A., Kristine E.E., Stephanie, L.H., Jane, A.C., Lisa, L., John, T.S., Deborah, M.K., Margaret, L.G., Jennifer, G.L., Lisa F., Nicolas N., Carolyn, J.C., Cora, E.L., Eric, S.O., Marcia, L.S., Peggy M.C.: Impact of Competing Risk of Mortality on Association of Weight Loss With Risk of Central Body Fractures in Older Men: A Prospective Cohort Study. J Bone Miner Res.; 32:624-632, 2017.

62. Mir-Mari, J., Wui, H., E Jung, R., Hämmerle, C. and Benic,G.: "Influence of blinded wound closure on the volume stability of different GBR materials: an in vitro cone beam computed tomographic examination". Clinical Oral Implants Research.; 27(2): 258-265, 2016.

63. Du, B., Liu, W., Deng, Y., Li, S., Liu, X., Gao, Y., Zhou, L. and Chen, J.: Angiogenesis and bone regeneration of porous nanohydroxyapatite/coralline blocks coated with rhVEGF165 in critical-size alveolar bone defects in vivo. International Journal of Nanomedicine; 10(1): 2555-2565, 2015.

64. Zhang, C., Yan, B., Cui, Z., Cui, S., Zhang, T., Wang, X., Liu, D., Yang, R., Jiang, N., Zhou, Y. and Liu, Y.: Bone regeneration in minipigs by intrafibrillarly-mineralized collagen loaded with autologous periodontal ligament stem cells.Scientific Reports 7, Article number: 10519, 2017.

65. Clark, R.A.: "Biology of dermal wound repair". Dermatologic clinics; 11(4): 647, 1993.

66. Vieira, A.E., Repeke, C.E., Ferreira Junior Sde, B., Colavite, P.M., Biguetti, C.C., Oliveira, R.C., Assis, G.F., Taga, R., Trombone, A.P. and Garlet, G.P.: Intramembranous Bone Healing Process Subsequent to Tooth Extraction in Mice: Micro-Computed Tomography, Histomorphometric and Molecular Characterization. PLoS One; 10(5): e0128021, 2015.

67. Venkatesan, J., Bhatnagar, I., Manivasagan, P., Kang, K.H. and Kim, S.K.: Alginate composites for bone tissue engineering: a review. Int J Biol Macromol; 72:269-281, 2015.

68. Gassling, V., Purcz, N., Braesen, J.H, Will, M, Gierloff, M., Behrens E., Açil, Y. and Wiltfang, J.: Comparison of two different absorbable membranes for the coverage of lateral osteotomy sites in maxillary sinus augmentation: A preliminary study. J. Cranio-Maxillofacial Surg.; 41, 76–82, 2013.

69. Ogundipe, O.K., Ugboko, V.I. and Owotade, F.J.: Can autologous platelet-rich plasma gel enhance healing after surgical extraction of mandibular third molars? J Oral Maxillofac Surg.; 69:2305-2310, 2011.

70. Brown, A. C. and Barker, T. H.: Fibrin-based biomaterials: Modulation of macroscopic properties through rational design at the molecular level. Acta Biomater; 10:1502–1514, 2014.

71. Cypher, T.J. and Grossman, J.P.: Biological principles of bone graft healing. J Foot Ankle Surg.; 35:413417, 1996.

72. Eriksson, C., Ohlson, K., Richter, K., Billerdahl, N., Johansson, M. and Nygren, H.: Callus formation and remodeling at titanium implants. J Biomed Mater Res A,; 83:10621069, 2007.

73. Knapen, M., Gheldof, D., Drion, P., Layrolle, P., Rompen, E. and Lambert, F.: Effect of Leukocyte- and Platelet-Rich Fibrin (L-PRF) on Bone Regeneration: A Study in Rabbits. Clin. Implant Dent. Relat. Res.; 17:143–152, 2015.

74. Fang, Z., Wang, Y., Feng, Q., Kienzle, A. and Müller, W.E.: Hierarchical structure and cytocompatibility of fish scales from Carassius auratus. Mater Sci Eng C Mater Biol Appl.; 43:145-52, 2014.

75. Pon-On, W., Suntornsaratoon, P., Charoenphandhu, N., Thongbunchoo, J., Krishnamra, N. and Tang, I.M.: Hydroxyapatite from fish scale for potential use as bone scaffold or regenerative material. Mater Sci Eng C Mater Biol Appl.; 62:183-189, 2016.

76. Kim, T.H., Kim, S.H., Sándor, G.K. and Kim, Y.D.: "Comparison of platelet-rich plasma (PRP), platelet-rich fibrin (PRF), and concentrated growth factor (CGF) in rabbit-skull defect healing". Archives of Oral Biology; 59(5): 550-558, 2014.

77. Jiwon, L., Jongman, L., Hui-Suk, Y., Hong-In, S., Eui-Kyun, Park.: Comparison of bone regeneration rate in flat and long bone defects: Calvarial and tibial bone. Tissue Engineering and Regenerative Medicine.; 10(6):336-340, 2013.

78. Kawase, T.: "Platelet-rich plasma and its derivatives as promising bioactive materials for regenerative medicine: basic principles and concepts underlying recent advances". Odontology;103(2):126-135, 2015.

79. Dohan Ehrenfest, D.M, Bielecki, T., Mishra, A., Borzini, P., Inchingolo, F., Sammartino, G., Rasmusson, L. and Everts, P.A.: "In search of a consensus terminology in the field of platelet concentrates for surgical use: platelet-rich plasma (PRP), platelet-rich fibrin (PRF), fibrin gel polymerization and leukocytes". Current Pharmaceutical Biotechnology; 13(7): 1131-1137, 2012.

80. Simonpieri, A., Del Corso, M., Sammartino, G. and Ehrenfest, D.M.D.: The relevance of choukroun's platelet-rich fibrin and metronidazole during complex maxillary rehabilitations using bone allograft. Part I: A new grafting protocol. Implant Dent.; 18:102-111, 2009.

81. Vence, B.S., Mandelaris, G.A. and Forbes, D.P.: Management of dent alveolar ridge defects for implant site development: An interdisciplinary approach. Comp. Cont. Educ. Dent.; 30(5):250-262, 2009.

82. Dohan, D.M., Choukroun, J., Diss, A., Dohan, S.L., Dohan, A.J.J., Mouhyi, J. and Gogly, B.: Platelet-rich fibrin (PRF): A second-generation platelet concentrate. Part III. Leukocyte activation: A new feature for platelet concentrates. Oral Surg. Oral Med. Oral Pathol. Oral Radiol. Endod.; 101:51-55, 2006.